



DATE PRESENTING CLINICAL SIGNS

9/9/2022

Enlarged liver with honeycomb appearance, larger hypoechoic nodule is 2cm diameter.

CYTOLOGY SUBMISSION

Liver

INTERPRETED BY

L.D. McGill, DVM,
Ph.D, DACVP

OBSERVATIONS

Liver: Submitted are 3 excellent videos of cells collected from the liver in Cocobean. The cellularity consists almost entirely of hepatocytes with mild to moderate vacuolization and mild granularity of the cytoplasm. There are some slight irregular changes suggesting the possibility of hyperplasia but there is no suggestion of malignant change. The major change appears to be the vacuolated change in the hepatocytes.

PATIENT

Cocobean Quant

INTERPRETATION OF THE FINDINGS & FURTHER RECOMMENDATIONS

Liver - Consistent with multifocal hepatocellular vacuolization and nodular hyperplasia

SPECIES COMMENTS

Canine

The cellular changes are suggestive of vacuolar hepatopathy and secondary nodular hyperplasia. There is no suggestion of malignancy or sepsis. There may be mild secondary inflammation. The vacuolar change could result in the honeycomb pattern described. These changes are often secondary to other problems including the potential of pancreatitis or enteritis. There is also a possibility that Cocobean will live a full life with this change which may or may not be pathologic.

BREED

Chihuahua

SEX

Male Neutered

AGE

11y

WEIGHT

17 lbs

HOSPITAL NAME

Rotterdam Veterinary
Hospital

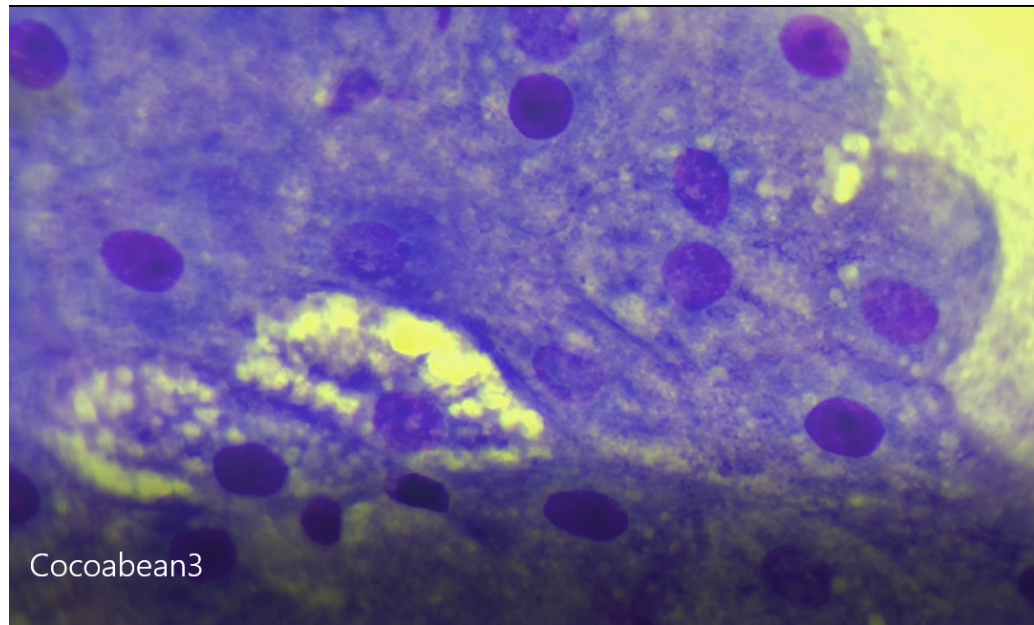


Image shows hepatocytes with vacuolization collected from Cocobean. Nodular hyperplasia is also possible.

REFERRING VET

Dr. St. Sir

The information and recommendations provided are based on the images presented by the referring veterinarian. No evaluation can be communicated regarding pathology that was not visible in the image/video clips provided.

INVOICE NUMBER

791



DATE Thank you for this referral. If the clinical or image interpretation does not parallel your findings or if I can be of any further assistance please contact me.

9/9/2022

INTERPRETED BY L.D. McGill, DVM, Ph.D., DACVP
8288 Top of the World Drive
Cottonwood Heights, UT 84121
ldmcgill.vetpath@gmail.com
cell: 801-865-1220

PATIENT

Cocobean Quant

SPECIES

Canine

BREED

Chihuahua

SEX

Male Neutered

AGE

11y

WEIGHT

17 lbs

HOSPITAL NAME

Rotterdam Veterinary
Hospital

REFERRING VET

Dr. St. Sir

INVOICE NUMBER

791