



**DATE PRESENTING CLINICAL SIGNS**

9/9/21

Acute onset anorexia and ADR on 8/23. Had lost 10 lbs since previous visit in 8/19. Treated with Amoxicillin, Metronidazole, Baytril, Denamarin and Prednisone 20mg SID x 5 days, then 10mg EOD x 1 week. On recheck on 9/2, eating and acting well, but LE more elevated and Bile Acids high.

PE: BCS 4/9.

**INTERPRETED BY**

L.D. McGill, DVM,  
Ph.D., DACVP

BW (8/23) ALT 701, Glob 2.1, rest WNL.

BW (9/2) ALT 805, ALP 486, GGT 8, Alb 6.3, and BA 40.

AUS: few distinct hyperechoic nodules, rest of liver had slightly heterogenous parenchyma (diffuse). R kidney very small, previous infarct?

**PATIENT CYTOLOGY SUBMISSION**

Athena Worsowicz

FNA of Liver

**OBSERVATIONS**

**SPECIES**

Canine

Liver: Submitted are 11 excellent videos of excellent to good collections of hepatocytes from the liver in Athena. The hepatocytes are aggregated with rather uniform nuclei. There is variation in the cytoplasm with some vacuolization and prominent granularity. There are scattered inflammatory cells observed but they are few. There are no criteria of malignancy or sepsis.

**BREED**

Boxer mix

**INTERPRETATION OF THE FINDINGS & FURTHER RECOMMENDATIONS**

Liver - Hepatocellular vacuolization and granularity with minimal inflammation.

**COMMENTS**

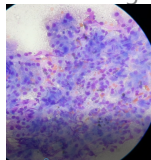
**SEX**

FS

The cellularity supports secondary metabolic changes in the liver of Athena. There is no suggestion of specific inflammation or neoplasia. These changes are likely due to endotoxin reaction or more likely due to response to the therapeutic agents particularly Pred. This is not an uncommon change when extensive therapy is instituted. These changes are likely reversible. They could be due to my favorite diagnosis that is difficult to confirm---Pancreatitis.

**AGE**

8 years



**WEIGHT**

61.2 lbs

Image shows a field of hepatocytes with mild vacuolization and granularity. There are very few inflammatory cells.

**The information and recommendations provided are based on the images presented by the referring veterinarian. No evaluation can be communicated regarding pathology that was not visible in the image/video clips provided.**

**HOSPITAL NAME**

Scanvet

Thank you for this referral. If the clinical or image interpretation does not parallel your findings or if I can be of any further assistance please contact me.

**REFERRING VET**

Dr. Sheridan

**L.D. McGill, DVM, Ph.D., DACVP**

8288 Top of the World Drive  
Cottonwood Heights, UT 84121  
ldmcgill.vetpath@gmail.com  
cell: 801-865-1220

**INVOICE NUMBER**

70402



**DATE**

9/9/21

**INTERPRETED BY**

L.D. McGill, DVM,  
Ph.D., DACVP

**PATIENT**

Athena Worsowicz

**SPECIES**

Canine

**BREED**

Boxer mix

**SEX**

FS

**AGE**

8 years

**WEIGHT**

61.2 lbs

**HOSPITAL NAME**

Scanvet

**REFERRING VET**

Dr. Sheridan

**INVOICE NUMBER**

70402