



DATE PRESENTING CLINICAL SIGNS

9/8/22

ADR; Vomiting and Diarrhea; Has a Hx of rear leg paresis and incontinence.
Leukocytosis w/ Left Shift and Monocytosis
Pancreas has a focal area of cystic/irregular tissue;

INTERPRETED BY CYTOLOGY SUBMISSION

Pancreas

L.D. McGill, DVM,
Ph.D, DACVP

OBSERVATIONS

Pancreas: Submitted are 9 excellent videos of very good collections of cells collected from the pancreas mass in Annie. The cellularity is rather consistent with packets of cells and individualized cells scattered throughout. There is prominent anisocytosis and anisokaryosis. The cells that are aggregated have prominent nucleoli. There are various structures that suggest acinar structures scattered throughout. There is minimal inflammation.

PATIENT

Annie Edmundson

INTERPRETATION OF THE FINDINGS & FURTHER RECOMMENDATIONS

SPECIES Pancreas - Consistent with pancreatic acinar carcinoma

Canine COMMENTS

The cellularity is strongly suggestive of a pancreatic acinar carcinoma. There are acinar structures scattered throughout. The cells appear to be derived from the pancreatic tissue. There is minimal inflammation. The anisocytosis and anisokaryosis strongly support carcinoma. Confirmation of the diagnosis will require follow-up exploratory and biopsy. Excision may prolong Annie's life. A guarded to unfavorable prognosis is warranted with this specific cellularity.

BREED

Collie

SEX

Female spayed

AGE

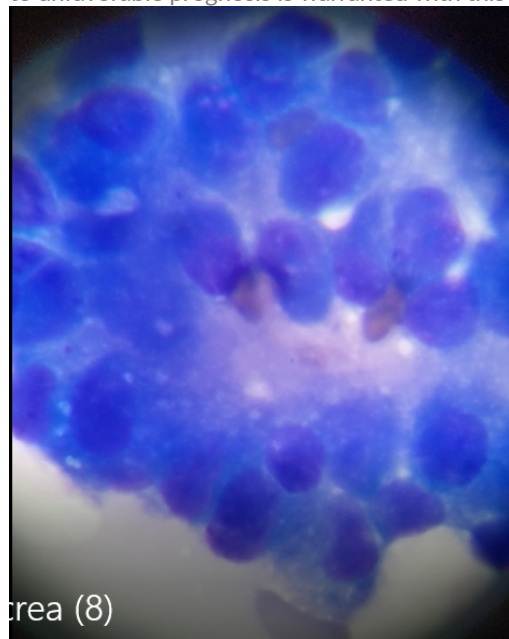
12y

WEIGHT

58 lbs

HOSPITAL NAME

Franklin Animal Clinic



pancrea (8)

Image shows a representative group of tumor cells collected from the pancreas in Annie. Note the anisocytosis and anisokaryosis in these cells

REFERRING VET

Dr. Doverspike

INVOICE NUMBER

789

The information and recommendations provided are based on the images presented by the referring veterinarian. No evaluation can be communicated regarding pathology that was not visible in the image/video clips provided.



DATE Thank you for this referral. If the clinical or image interpretation does not parallel your findings or if I can be of any further assistance please contact me.

9/8/22

INTERPRETED BY L.D. McGill, DVM, Ph.D., DACVP
8288 Top of the World Drive
Cottonwood Heights, UT 84121
ldmcgill.vetpath@gmail.com
cell: 801-865-1220

PATIENT

Annie Edmundson

SPECIES

Canine

BREED

Collie

SEX

Female spayed

AGE

12y

WEIGHT

58 lbs

HOSPITAL NAME

Franklin Animal Clinic

REFERRING VET

Dr. Doverspike

INVOICE NUMBER

789