



DATE PRESENTING CLINICAL SIGNS

9/7/22 Lethargic, anorexic, hiding in closet for a few days, soft tissue mass R caudal ventral thorax on CXR, segment of thickened SI on AXR. Current meds: Transdermal Mirtazapine
Neuts 10,823, Monos 1233, TBili 0.9

INTERPRETED BY

L.D. McGill, DVM,
Ph.D, DACVP

CYTOLOGY SUBMISSION

FNA of Stomach mass

PATIENT

Possum Van Dyk

OBSERVATIONS

Stomach mass: Submitted are 8 excellent videos of excellent collections of cells from the stomach mass in Possum. The cellularity is mixed. The majority of the cells are macrophages or histiocytic cells with scattered spindle cells, neutrophils and lymphocytes. Red blood cells are present in the surrounding parenchyma and large numbers. The collection is most characteristic of an inflammatory process. Malignant criteria are not identified.

SPECIES

Feline

BREED

DSH

INTERPRETATION OF THE FINDINGS & FURTHER RECOMMENDATIONS

Stomach mass - Pyogranulomatous inflammation with scattered hepatocytes. (See comments)

COMMENTS

SEX The cellularity is characteristic of a pyogranulomatous inflammatory process. The most common cause of this type of reaction in the adult cat is the dry form of feline infectious peritonitis. I did not identify malignant characteristics in the cellular collection. Hepatocytes were present but there is a marked inflammatory process which probably is not in the liver. At this time further evaluation for feline coronavirus is encouraged. There is a possibility that the coronavirus test could be done on the cells on these slides. Collections from other sources may also be beneficial. There are some fields that have increased lymphoid cells which may suggest lymphoma, but I cannot make that diagnosis. With the cells that we have, an unfavorable prognosis is warranted in my opinion. There could be another source for chronic inflammation but with the multiple lesions, FIP is most likely.

AGE 10y

WEIGHT

9.2#

HOSPITAL NAME

Tranquility Veterinary
Clinic

REFERRING VET

Dr. House

INVOICE NUMBER

40596



DATE

9/7/22

INTERPRETED BY

L.D. McGill, DVM,
Ph.D, DACVP

PATIENT

Possum Van Dyk

SPECIES

Feline

BREED

DSH

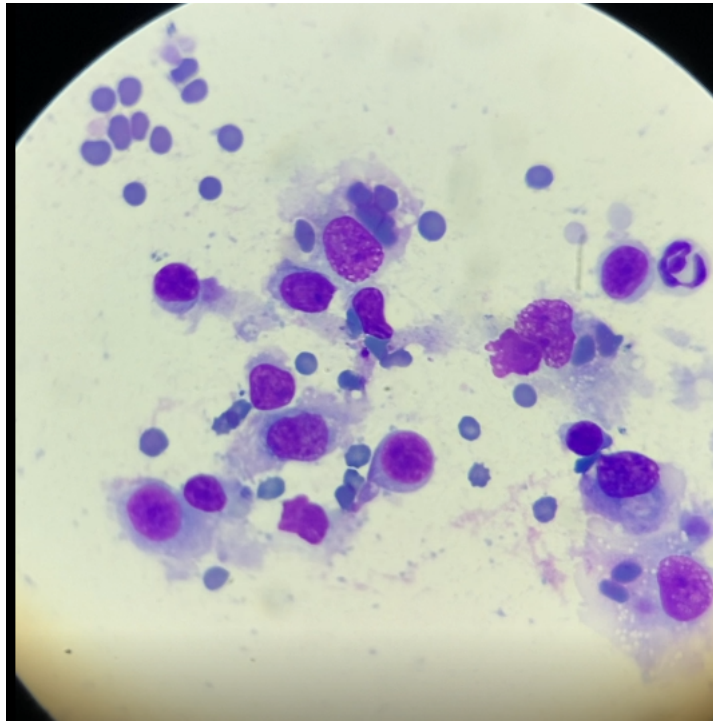


Image shows a large number of macrophages with some lymphoid cells and a neutrophil. Due to the mixed cellularity, inflammation appears most likely.

SEX

FS

The information and recommendations provided are based on the images presented by the referring veterinarian. No evaluation can be communicated regarding pathology that was not visible in the image/video clips provided.

AGE

10y

Thank you for this referral. If the clinical or image interpretation does not parallel your findings or if I can be of any further assistance, please contact me.

WEIGHT

9.2#

L.D. McGill, DVM, Ph.D., DACVP
8288 Top of the World Drive
Cottonwood Heights, UT 84121
ldmcgill.vetpath@gmail.com
cell: 801-865-1220

HOSPITAL NAME

Tranquility Veterinary
Clinic

REFERRING VET

Dr. House

INVOICE NUMBER

40596