



DATE PRESENTING CLINICAL SIGNS

9/7/22

Patient presents for FNA of intestinal mass. Pertinent U/S findings from 9/1/22: "The stomach itself was unremarkable. A 4.87 cm x 5.36 cm jejunal mass was noted cranial to the urinary bladder with minor serosal escape into the regional omentum caudally towards the bladder itself. This mass is stricturing with a mild amount of obstructive pattern."

INTERPRETED BY

L.D. McGill, DVM,
Ph.D, DACVP

CYTOLOGY SUBMISSION

FNA of intestinal mass

PATIENT

Henry Freylikham

OBSERVATIONS

Intestinal mass: Submitted are several excellent videos and images of cells collected from the intestinal mass in Henry. There are several packets of cells that demonstrate elongated spindle cells with elongated nuclei. These nuclei are dark, and cigar shaped. The spindle cell proliferation is the most prominent collection in the submission. There are some aggregates that are quite large. Several smaller aggregates are present. There are scattered inflammatory cells throughout the collection, but they are few in numbers.

SPECIES

Canine

INTERPRETATION OF THE FINDINGS & FURTHER RECOMMENDATIONS

BREED

Intestinal mass - Spindle cell tumor suggestive of leiomyosarcoma or possible GIST tumor

Coton du Tulear

COMMENTS

SEX

Male Neutered

The cellularity supports the likelihood of one of the two tumors listed. These growths rarely metastasis but the only means of therapy that I know is excision. Exploratory, biopsy or excision is encouraged for therapy. A guarded prognosis is warranted until the mass can be confirmed and removed.

AGE

14y

WEIGHT

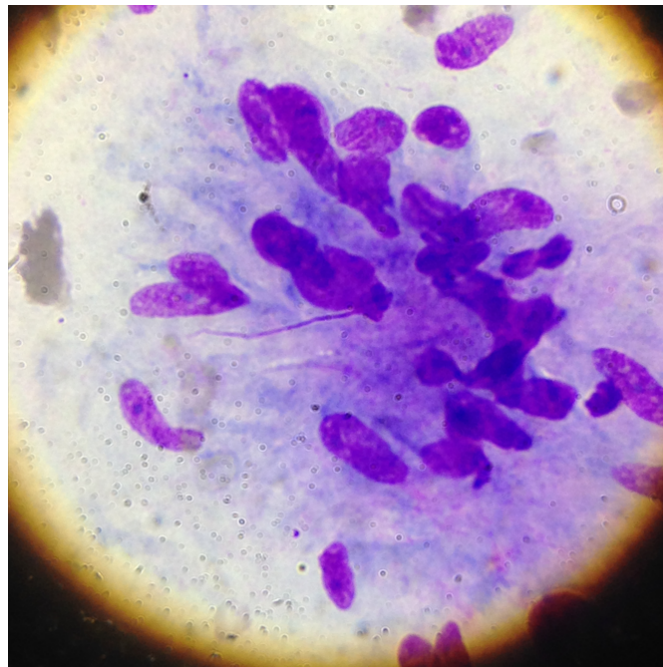
11.8 lbs

HOSPITAL NAME

Franklin Lakes
Animal Hospital

REFERRING VET

Dr. Ward



INVOICE NUMBER

40597

Image shows some of the spindle cells collected from the intestinal mass in Henry. Note the cigar shaped nuclei.



DATE 9/7/22 The information and recommendations provided are based on the images presented by the referring veterinarian. No evaluation can be communicated regarding pathology that was not visible in the image/video clips provided.

INTERPRETED BY L.D. McGill, DVM, Ph.D., DACVP Thank you for this referral. If the clinical or image interpretation does not parallel your findings or if I can be of any further assistance, please contact me.

L.D. McGill, DVM,
Ph.D., DACVP

L.D. McGill, DVM, Ph.D., DACVP
8288 Top of the World Drive
Cottonwood Heights, UT 84121
ldmcgill.vetpath@gmail.com
cell: 801-865-1220

PATIENT

Henry Freylikham

SPECIES

Canine

BREED

Coton du Tulear

SEX

Male Neutered

AGE

14y

WEIGHT

11.8 lbs

HOSPITAL NAME

Franklin Lakes
Animal Hospital

REFERRING VET

Dr. Ward

INVOICE NUMBER

40597