



DATE PRESENTING CLINICAL SIGNS

9/7/2021 The cat received the rabies vaccine on 19th of August. The cat was brought for general check up today and I noticed a small lump in the interscapular region. FNA of the lump was done to rule out feline injection site sarcoma. No other complains. The cat is BAR.

INTERPRETED BY CYTOLOGY SUBMISSION

L.D. McGill, DVM, Ph.D, DACVP Lump at interscapular region.

PATIENT OBSERVATIONS

Milo Sara Subcutaneous mass: Submitted is 1 good video of good collections of cells from the interscapular subcutaneous mass on Milo. The cellularity is mixed with large numbers of eosinophils and free eosinophilic granules. There are scattered macrophages and lymphocytes. There are no suggestions of malignancy.

SPECIES INTERPRETATION OF THE FINDINGS & FURTHER RECOMMENDATIONS

Feline Subcutaneous mass: Focal chronic eosinophilic and granulomatous inflammation.

BREED COMMENTS

DSH This cellularity is very characteristic of a localized inflammatory process and likely an injection site granuloma with large numbers of eosinophils. There is no suggestion of neoplasia and I would not expect that type of change in this age of cat. After studying this tumor for many years, injection site sarcomas are extremely rare at this age. Injection site granulomas are not uncommon and they are expected to disappear within 2 months. I expect a favorable response.

SEX

Male

AGE

3-month-old

WEIGHT

2.3 lbs

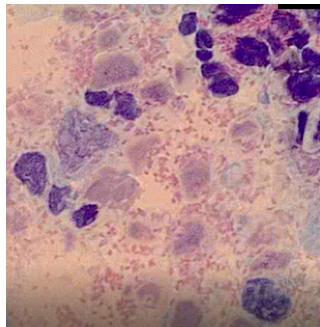


Image shows a mixture of cells with a background of RBCs and eosinophilic granules with neutrophils and lymphocytes in the upper right collected from the mass on Milo.

HOSPITAL NAME

City Veterinary Clinic
Alain

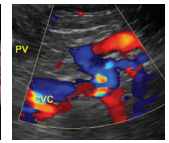
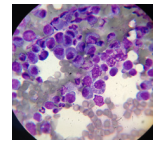
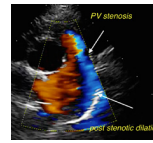
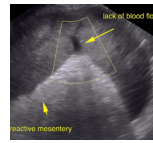
The information and recommendations provided are based on the images presented by the referring veterinarian. No evaluation can be communicated regarding pathology that was not visible in the image/video clips provided.

Thank you for this referral. If the clinical or image interpretation does not parallel your findings or if I can be of any further assistance please contact me.

REFERRING VET

Inam ul haq

L.D. McGill, DVM, Ph.D., DACVP
8288 Top of the World Drive
Cottonwood Heights, UT 84121
ldmcgill.vetpath@gmail.com
cell: 801-865-1220



DATE

9/7/2021

INTERPRETED BY

L.D. McGill, DVM,
Ph.D, DACVP

PATIENT

Milo Sara

SPECIES

Feline

BREED

DSH

SEX

Male

AGE

3-month-old

WEIGHT

2.3 lbs

HOSPITAL NAME

City Veterinary Clinic
Alain

REFERRING VET

Inam ul haq