

**DATE PRESENTING CLINICAL SIGNS**

9/4/21 Large left liver mass with moth eaten appearance, remaining liver parenchyma slightly mottled

**INTERPRETED BY CYTOLOGY SUBMISSION**

L.D. McGill, DVM, Ph.D., DACVP

FNA of liver mass

**OBSERVATIONS**

**PATIENT** Liver: Submitted are 7 excellent videos and 1 image of cells collected from the liver in Hudson. There are excellent collections of hepatocytes in all of the videos and in the image. The surrounding red cells include a few inflammatory cells that are neutrophils and lymphocytes. The hepatocytes demonstrate slightly irregular cytoplasm and aggregates of cells. They do not appear to be growing in chain-like patterns. The nuclear structures in the hepatocytes are rather uniform. I am unable to identify criteria of malignancy.

Sherwood Hudson

**SPECIES**

Canine

**INTERPRETATION OF THE FINDINGS & FURTHER RECOMMENDATIONS**

**BREED**

Liver - Excellent aggregates of hepatocytes suggesting nodular hyperplasia with mild inflammation

Lab mix

**COMMENTS**

**SEX**  
Male Neutered

The changes in these hepatocytes suggest the possibility of nodular hyperplasia. I cannot completely rule out the possibility of a very low-grade hepatocellular adenoma but in general it does not have that appearance. The vacuolization could be due to irregular vascular structures within the mass or possibly more fluid in some hepatocytes. With the collection present, there are no suggestions of malignancy or sepsis. Follow-up biopsy may be required to confirm the process in the liver. Hudson may be capable of living with this process for a lifetime.

**AGE**

10 years

**WEIGHT**

55#

**The information and recommendations provided are based on the images presented by the referring veterinarian. No evaluation can be communicated regarding pathology that was not visible in the image/video clips provided.**

Thank you for this referral. If the clinical or image interpretation does not parallel your findings or if I can be of any further assistance please contact me.

**HOSPITAL NAME**

Rockaway Animal Hospital

**L.D. McGill, DVM, Ph.D., DACVP**

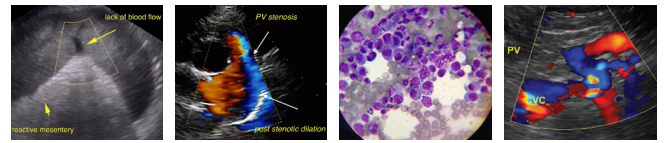
8288 Top of the World Drive  
Cottonwood Heights, UT 84121  
ldmcgill.vetpath@gmail.com  
cell: 801-865-1220

**REFERRING VET**

Dr. Maniar

**INVOICE NUMBER**

80294



**DATE**

9/4/21

**INTERPRETED BY**

L.D. McGill, DVM, Ph.D, DACVP

**PATIENT**

Sherwood Hudson

**SPECIES**

Canine

**BREED**

Lab mix

**SEX**

Male Neutered

**AGE**

10 years

**WEIGHT**

55#

**HOSPITAL NAME**

Rockaway Animal Hospital

**REFERRING VET**

Dr. Maniar

**INVOICE NUMBER**

80294

