



DATE PRESENTING CLINICAL SIGNS

9/30/21

The owner noticed that the cat look and acting different for two weeks. They thought that she maybe in-heat. The owner also observed that the abdomen is bigger than normal. The night before they plan to bring the cat for spaying, the cat was isolated in a room. in the morning they found a huge amount of vomitus which appears like feces. Also the abdomen became less distended. In the afternoon they decided to bring the cat in vet clinic for check up.

INTERPRETED BY

L.D. McGill, DVM,
Ph.D, DACVP

The cat appears lethargic. The abdomen is tendred and on palpation the gut is filled with gas. The cat is a little uncomfortable during the physical examination. Heart and respiration rate are increased. Temperature is normal

PATIENT CYTOLOGY SUBMISSION

Dr. Klaus Pinky

FNA of Unidentified source

OBSERVATIONS

SPECIES

Feline

Unidentified source: Submitted is 1 good video of cells collected from an unidentified abdominal source in Pinky. The cells are almost all lymphocytes. There are scattered RBCs. There is some protein fluid in the background.

INTERPRETATION OF THE FINDINGS & FURTHER RECOMMENDATIONS

BREED

Unidentified source - Fields of mature lymphocytes

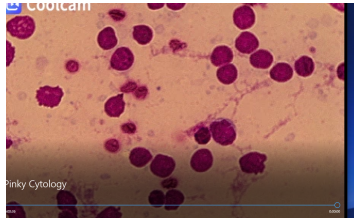
Siamese

COMMENTS

This collection is mature lymphocytes primarily. If this is a lymph node then it is normal or reactive. If associated with the intestine, then a small cell lymphoma is possible. Hopefully your understanding of the source will be beneficial in identifying the potential process.

SEX

Female



AGE

3 years

Image shows a field of lymphocytes collected from the abdomen in Pinky

WEIGHT

2.6#

The information and recommendations provided are based on the images presented by the referring veterinarian. No evaluation can be communicated regarding pathology that was not visible in the image/video clips provided.

HOSPITAL NAME

City Veterinary Clinic
Alain

Thank you for this referral. If the clinical or image interpretation does not parallel your findings or if I can be of any further assistance please contact me.

L.D. McGill, DVM, Ph.D., DACVP

8288 Top of the World Drive
Cottonwood Heights, UT 84121

REFERRING VET

Dr. Eric dela Cruz

ldmcgill.vetpath@gmail.com
cell: 801-865-1220

INVOICE NUMBER

70411



DATE

9/30/21

INTERPRETED BY

L.D. McGill, DVM,
Ph.D., DACVP

PATIENT

Dr. Klaus Pinky

SPECIES

Feline

BREED

Siamese

SEX

Female

AGE

3 years

WEIGHT

2.6#

HOSPITAL NAME

City Veterinary Clinic
Alain

REFERRING VET

Dr. Eric dela Cruz

INVOICE NUMBER

70411