



**DATE PRESENTING CLINICAL SIGNS**

9/29/22

Patient presented 9/29/22 for recheck from swollen papliteal lymph node. Owner noticed several new masses. Masse on top of head was aspirated.

**INTERPRETED BY**

**CYTOLOGY SUBMISSION**

Head mass

L.D. McGill, DVM,  
Ph.D, DACVP

**OBSERVATIONS**

Head mass: Submitted is a single excellent collection of cells from the mass on the head on Henry. The cellularity consists of a proliferation of round to irregular cells. Many of the cells have light metachromatic to purple granules in their cytoplasm. There is prominent anisocytosis and anisokaryosis. Scattered eosinophils are present. There appear to be some lymphocytes present. There is a background of granules that suggest metachromatic granules from mast cells.

**PATIENT**

Henry Korkosz

**INTERPRETATION OF THE FINDINGS & FURTHER RECOMMENDATIONS**

Head mass - Consistent with mast cell tumor, probably high-grade.

**SPECIES**

Canine

**COMMENTS**

From the earlier description of this case from the other sample from Henry, I suspected that this collection was from the lymph node but it is not, it is from the head. This head lesion demonstrates more characteristics suggestive of mast cell tumor. The cells are irregularly to poorly granulated. Many of the cells are degranulated and granules are present in the background. This is strongly suggestive of a high-grade mast cell tumor. Many mast cell tumors on the head of dogs are more aggressive. Wide excision with chemotherapy can be considered. The spleen and liver should be evaluated to determine if there is potential mast cell tumor in those organs particularly since multiple lesions are identified in the skin. A guarded to unfavorable prognosis is warranted in my opinion.

**BREED**

Chihuahua

**SEX**

SF

**AGE**

13y

**WEIGHT**

8.1#

**HOSPITAL NAME**

Rotterdam Veterinary  
Hospital

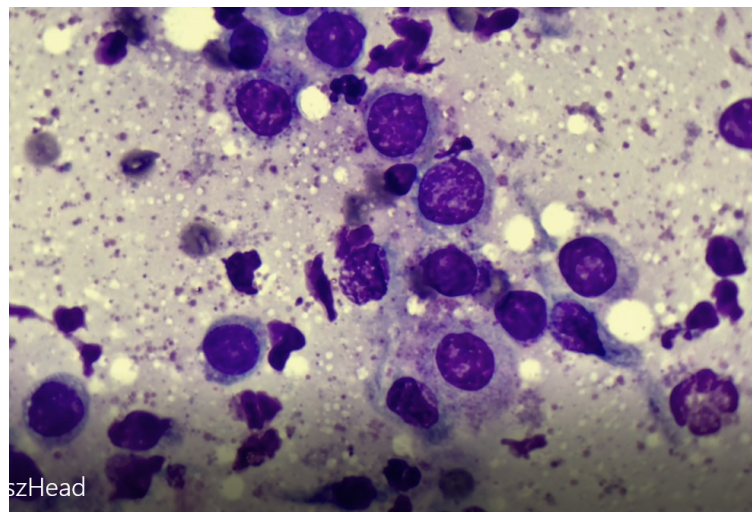


Image shows a group of cells collected from the head on Henry. Several show some granules in the cytoplasm and there are free granules in the background. Note the eosinophil to the lower right.

**REFERRING VET**

Dr. St. Sir

The information and recommendations provided are based on the images presented by the referring veterinarian. No evaluation can be communicated regarding pathology that was not visible in the image/video clips provided.

**INVOICE NUMBER**

813



**DATE** Thank you for this referral. If the clinical or image interpretation does not parallel your findings or if I can be of any further assistance please contact me.

9/29/22

**INTERPRETED BY** L.D. McGill, DVM, Ph.D., DACVP  
8288 Top of the World Drive  
Cottonwood Heights, UT 84121  
ldmcgill.vetpath@gmail.com  
cell: 801-865-1220

**PATIENT**

Henry Korkosz

**SPECIES**

Canine

**BREED**

Chihuahua

**SEX**

SF

**AGE**

13y

**WEIGHT**

8.1#

**HOSPITAL NAME**

Rotterdam Veterinary  
Hospital

**REFERRING VET**

Dr. St. Sir

**INVOICE NUMBER**

813