



DATE PRESENTING CLINICAL SIGNS

9/28/2021 FNA of spleen.

CYTOLOGY SUBMISSION

U/S-guided FNA.

INTERPRETED BY

L.D. McGill, DVM,
Ph.D, DACVP

OBSERVATIONS

Spleen: Submitted are 4 excellent videos of excellent collections of cells from the spleen in Bart. The cellularity is mixed. It includes large numbers of nucleated RBCs with neutrophils, megakaryocytes and scattered lymphocytes throughout all of the smears. The major cellularity includes all of the nucleated RBCs and megakaryocytes. This supports strong active extra medullary hematopoiesis. There is no suggestion of neoplasia or sepsis. There may be mild inflammation.

PATIENT

Bart Slay

INTERPRETATION OF THE FINDINGS & FURTHER RECOMMENDATIONS

Spleen - Marked extramedullary hematopoiesis with mild inflammation and no evidence of malignancy.

SPECIES

Canine

COMMENTS

The changes in this excellent splenic collection with the excellent videos strongly support very active hematopoiesis. This supports strong extramedullary hematopoiesis. There could be mild inflammation. I did not identify changes that would support hemolysis or erythrophagocytosis but that could also be present in some part of the spleen. At this time the changes are very characteristic of extramedullary hematopoiesis. There is no suggestion of neoplasia or sepsis in this collection.

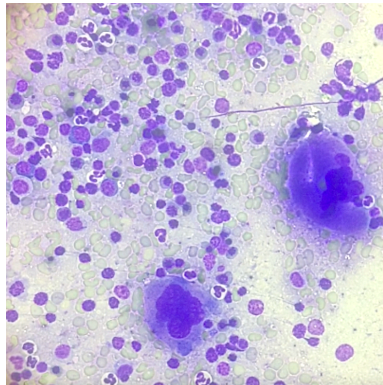
BREED

Golden Retriever

SEX

Image below shows a representative cellularity from the spleen in Bart. There are prominent megakaryocytes with nucleated RBCs and neutrophils.

Male neutered



AGE

10-year-old

WEIGHT

79.2 lbs

HOSPITAL NAME

South Willamette VC

REFERRING VET

Dr. Willamen

The information and recommendations provided are based on the images presented by the referring veterinarian. No evaluation can be communicated regarding pathology that was not visible in the image/video clips provided.

Thank you for this referral. If the clinical or image interpretation does not parallel your findings or if I can be of any further assistance please contact me.



DATE

9/28/2021

L.D. McGill, DVM, Ph.D., DACVP

8288 Top of the World Drive
Cottonwood Heights, UT 84121
ldmcgill.vetpath@gmail.com
cell: 801-865-1220

INTERPRETED BY

L.D. McGill, DVM,
Ph.D., DACVP

PATIENT

Bart Slay

SPECIES

Canine

BREED

Golden Retriever

SEX

Male neutered

AGE

10-year-old

WEIGHT

79.2 lbs

HOSPITAL NAME

South Willamette VC

REFERRING VET

Dr. Willamen