



DATE PRESENTING CLINICAL SIGNS

9/27/21

straining to urinate and defecate. extensive small intestinal mass noted, FNA performed

CYTOLOGY SUBMISSION

FNA of intestinal mass

INTERPRETED BY

L.D. McGill, DVM,
Ph.D., DACVP

OBSERVATIONS

Intestinal mass: Submitted are 7 good to excellent videos of cells collected from the intestinal mass in Leonidas. There is one image that demonstrates the same change present in 4 of the videos. This consists of hemorrhage with aggregates of platelets. There are scattered inflammatory cells in these videos and the image. Three of the videos demonstrate excellent collections of round cells that are extremely pleomorphic with many of the cells showing large nuclei and prominent nucleoli. There are scattered inflammatory cells in these videos as well. In several locations the cells are packeted in large numbers. There are scattered macrophages identified.

PATIENT

Leonidas McNamara

SPECIES INTERPRETATION OF THE FINDINGS & FURTHER RECOMMENDATIONS

feline

Intestinal mass - Consistent with high grade intestinal lymphoma.

COMMENTS

BREED

DSH

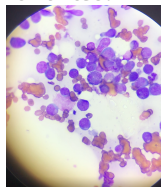
The cellularity in the 3 excellent smears of round cells is most consistent with a high-grade lymphoma. This would have to be an intestinal lymphoma. Very likely other organs are not involved since intestinal lymphoma often has markers that limit growth to the intestine. Some of the cells have granular cytoplasm supporting large granular lymphoid cells. This may be a T or B-cell lymphoma. Immunophenotyping can be performed on these smears but it may not be as beneficial in prognosis as in the dog. There is evidence in the literature that suggests that excision of these lymphoma masses from the intestine can prolong the life of Leonidas. A long-term unfavorable prognosis is warranted.

SEX

Male Neutered

AGE

12y



WEIGHT

12.5#

Image shows a representative collection of round cells from the intestinal mass in Leonidas. Note the larger cells with an eosinophil to the right, center. There are also small lymphocytes.

The information and recommendations provided are based on the images presented by the referring veterinarian. No evaluation can be communicated regarding pathology that was not visible in the image/video clips provided.

HOSPITAL NAME

Rockaway Animal
Hospital

Thank you for this referral. If the clinical or image interpretation does not parallel your findings or if I can be of any further assistance please contact me.

L.D. McGill, DVM, Ph.D., DACVP

REFERRING VET

Dr Maniar

8288 Top of the World Drive
Cottonwood Heights, UT 84121
ldmcgill.vetpath@gmail.com
cell: 801-865-1220

INVOICE NUMBER

70410



DATE

9/27/21

INTERPRETED BY

L.D. McGill, DVM,
Ph.D., DACVP

PATIENT

Leonidas McNamara

SPECIES

feline

BREED

DSH

SEX

Male Neutered

AGE

12y

WEIGHT

12.5#

HOSPITAL NAME

Rockaway Animal
Hospital

REFERRING VET

Dr Maniar

INVOICE NUMBER

70410