



**DATE PRESENTING CLINICAL SIGNS**

9/26/22 owner recently noted lump below the skin left angle jaw  
has history of melanoma

**INTERPRETED BY CYTOLOGY SUBMISSION**

Skin lesion

L.D. McGill, DVM,  
Ph.D, DACVP

**OBSERVATIONS**

Skin lesion: Submitted are 6 excellent videos of minimal to moderate collections of cells from the skin lump on the jaw on Jack. The nucleated cellularity is mixed. The background is almost entirely red blood cells with protein. The red blood cells have different colorations in some of the smears. The nucleated cells include small mature lymphocytes, neutrophils, reactive lymphocytes, macrophages and I think there was one or two eosinophils. I found no characteristics of malignancy in any of the cells. I was unable to identify pigment in any of the cells.

**PATIENT**

Jack Osnow

**INTERPRETATION OF THE FINDINGS & FURTHER RECOMMENDATIONS**

**SPECIES** Skin lesion - Consistent with pyogranulomatous inflammation and hemorrhage.

Canine

**COMMENTS**

The cellularity in this collection supports chronic inflammation. This could be secondary to many different conditions or even secondary to trauma or a foreign body penetration. I did not identify changes to support malignancy or sepsis. This inflammatory process could be the result of degeneration occurring secondarily from some other proliferative process but that type of reaction is not identified in this collection. Biopsy or removal of the mass with a follow-up histopathology evaluation will be required to confirm the process. Due to the potential of inflammation, anti-inflammatory agents may be beneficial in decreasing the size of the lesion.

**BREED**

Golden Retriever

**SEX**

Male Neutered

**AGE**

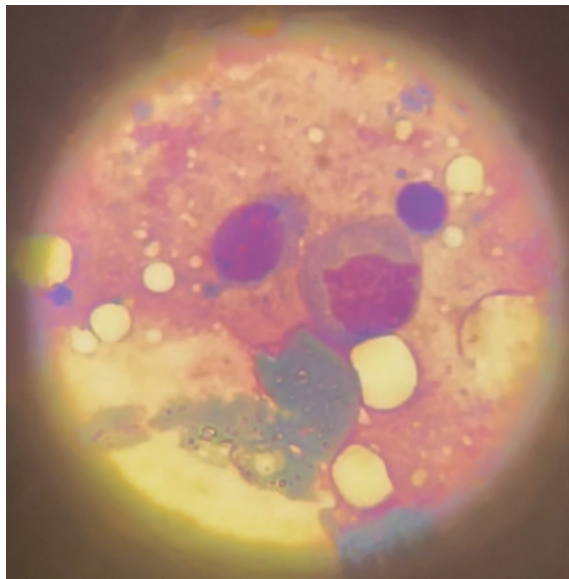
10y

**WEIGHT**

62

**HOSPITAL NAME**

Green Mountain  
Veterinary Hospital



**REFERRING VET**

Dr. Treat Jr

Image shows a macrophage with a small lymphocyte and a large reactive lymphocyte associated with RBCs collected from Jack. The protein background is prominent.

**INVOICE NUMBER**

808

The information and recommendations provided are based on the images presented by the referring veterinarian. No evaluation can be communicated regarding pathology that was not visible in the image/video clips provided.



**DATE**

9/26/22

Thank you for this referral. If the clinical or image interpretation does not parallel your findings or if I can be of any further assistance please contact me.

**INTERPRETED BY**

L.D. McGill, DVM,  
Ph.D, DACVP

**L.D. McGill, DVM, Ph.D., DACVP**  
8288 Top of the World Drive  
Cottonwood Heights, UT 84121  
ldmcgill.vetpath@gmail.com  
cell: 801-865-1220

**PATIENT**

Jack Osnow

**SPECIES**

Canine

**BREED**

Golden Retriever

**SEX**

Male Neutered

**AGE**

10y

**WEIGHT**

62

**HOSPITAL NAME**

Green Mountain  
Veterinary Hospital

**REFERRING VET**

Dr. Treat Jr

**INVOICE NUMBER**

808