



DATE PRESENTING CLINICAL SIGNS

9/21/22

US showed non-specific diffuse hepatopathy, prominent in size with slightly swollen peripheral contours. Diffusely mottled in appearance with ill-defined hypoechoic areas. Elevated ALT found on bloodwork.

INTERPRETED BY

L.D. McGill, DVM,
Ph.D, DACVP

CYTOLOGY SUBMISSION

FNA of Liver

PATIENT

Casey Ramos

OBSERVATIONS

Liver: Submitted are 5 excellent videos of cells collected from the liver in Casey. The hepatocytes demonstrate vacuolization and granularity. There are scattered inflammatory cells in the surrounding red blood cells. The hepatocytes are slightly clumped which could suggest hyperplasia but there are no changes to support malignancy. The inflammation is mild and secondary.

SPECIES

Canine

INTERPRETATION OF THE FINDINGS & FURTHER RECOMMENDATIONS

Liver - Hepatocellular vacuolization and granularity with mild inflammation and possible nodular hyperplasia. (see comments)

BREED

terrier mix

COMMENTS

The cellular changes in the hepatocytes are not specific for any primary liver disease. These changes suggest the possibility of secondary vacuolar hepatopathy. There is some mild inflammation which could be secondary due to enteritis pancreatitis or other types of inflammation. Nodular hyperplasia is possible with this cellular change. At this time, the liver aspirates do not support any evidence of primary neoplasia or sepsis. Continued monitoring of other organs is encouraged to identify any underlying process.

AGE

10years

WEIGHT

22.9#

HOSPITAL NAME

Animal Care Centers of
Flanders

REFERRING VET

Dr. Hallihan

INVOICE NUMBER

40608

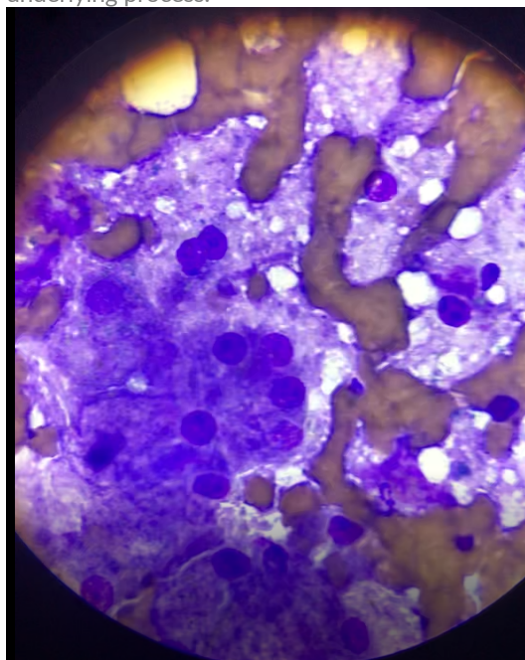


Image shows a representative group of hepatocytes with vacuolization and possible nodular hyperplasia in the liver in Casey. There is minimal inflammation.



DATE 9/21/22 The information and recommendations provided are based on the images presented by the referring veterinarian. No evaluation can be communicated regarding pathology that was not visible in the image/video clips provided.

INTERPRETED BY L.D. McGill, DVM, Ph.D., DACVP Thank you for this referral. If the clinical or image interpretation does not parallel your findings or if I can be of any further assistance, please contact me.

L.D. McGill, DVM,
Ph.D., DACVP

L.D. McGill, DVM, Ph.D., DACVP
8288 Top of the World Drive
Cottonwood Heights, UT 84121
ldmcgill.vetpath@gmail.com
cell: 801-865-1220

PATIENT

Casey Ramos

SPECIES

Canine

BREED

terrier mix

SEX

Male Neutered

AGE

10years

WEIGHT

22.9#

HOSPITAL NAME

Animal Care Centers of
Flanders

REFERRING VET

Dr. Hallihan

INVOICE NUMBER

40608