



DATE PRESENTING CLINICAL SIGNS

9/20/22

Small 5 mm black cystic like skin mass on dorsal head. Black fluid aspirated

CYTOLOGY SUBMISSION

Skin mass

INTERPRETED BY

L.D. McGill, DVM,
Ph.D, DACVP

OBSERVATIONS

Skin mass: Submitted are 10 excellent images of moderate nucleated cellular collections from the skin mass on the dorsal head from Maggie. There are large numbers of yellowish-brown granules throughout the collection. There are scattered macrophages with foamy to vacuolated cytoplasm. Other specific cellularity is not identified. There may be some inflammatory cells but much of the tissue is protein and necrotic tissue.

PATIENT

Maggie Mayhew

INTERPRETATION OF THE FINDINGS & FURTHER RECOMMENDATIONS

Skin mass on dorsal head - Necrotic fluid-filled cyst with hemosiderin or melanin pigment and macrophages.

SPECIES

Feline

COMMENTS

The cellularity in this collection is not specific. There is necrosis and there is degenerate debris and there is pigment. The pigment could be melanin or possibly hemosiderin granules but I think they are melanin. This would suggest some type of pigmented cystic structure. It appears to be benign with this large cyst center. Excision of the mass would be encouraged. There is no suggestion of malignancy or sepsis.

BREED

DLH

SEX

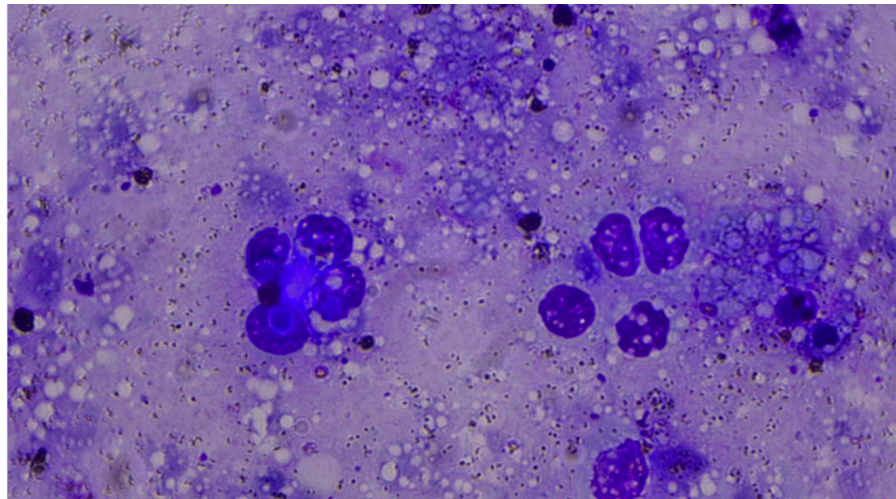
Female Spayed

AGE

12y

WEIGHT

9 lbs



HOSPITAL NAME

Image shows pigment throughout the protein and debris with macrophages and necrotic cells. Much of the reaction is necrotic.

Central Veterinary
Hospital

REFERRING VET

Dr. St Sir

The information and recommendations provided are based on the images presented by the referring veterinarian. No evaluation can be communicated regarding pathology that was not visible in the image/video clips provided.

Thank you for this referral. If the clinical or image interpretation does not parallel your findings or if I can be of any further assistance please contact me.

INVOICE NUMBER

804



DATE L.D. McGill, DVM, Ph.D., DACVP

9/20/22
8288 Top of the World Drive
Cottonwood Heights, UT 84121
ldmcgill.vetpath@gmail.com
cell: 801-865-1220

INTERPRETED BY

L.D. McGill, DVM,
Ph.D., DACVP

PATIENT

Maggie Mayhew

SPECIES

Feline

BREED

DLH

SEX

Female Spayed

AGE

12y

WEIGHT

9 lbs

HOSPITAL NAME

Central Veterinary
Hospital

REFERRING VET

Dr. St Sir

INVOICE NUMBER

804