



**DATE PRESENTING CLINICAL SIGNS**

9/20/22

Limping last 2 weeks, has had neck pain in the past, owner restarted Prednisone which did not help.  
Abnormal CBC attached

**INTERPRETED BY CYTOLOGY SUBMISSION**

L.D. McGill, DVM,  
Ph.D, DACVP

Blood smear

**PATIENT**

Loki Dunbar

**OBSERVATIONS**

Blood smear: Submitted are 6 excellent videos of a poorly preserved blood smear collected from Loki. The red blood cells are almost all crenated and there are scattered large red blood cells. Leukocytes are contracted and difficult to identify since they appear to be old leukocytes. Many of the nucleated cells in my opinion appear to be nucleated RBCs. I am questioning the accuracy of the automated CBC results. The problem is due to this being old blood or blood that was stored in the refrigerator or associated with too much heat, I'm unable to be certain as to CBC results.

**SPECIES INTERPRETATION OF THE FINDINGS & FURTHER RECOMMENDATIONS**

Canine

Blood smear - Marked artifactual changes in the blood suggesting refrigeration or heating of the blood prior to smearing. (see comments)

**BREED**

Border Collie, Mixed  
Collie

**COMMENTS**

I am sorry that I am unable to interpret this blood smear adequately. The red blood cells are altered markedly as a result of refrigeration, heating or something. The leukocytes are old and degenerate and there are cells that appear to be nucleated red blood cells but I cannot confirm that. Nucleated RBCs were suspected on the automated CBC results. You will have some familiarity with how this blood was handled. A repeat collection with the goal of making blood smears immediately upon drawing blood will likely result in a good smear that can be interpreted. Of course we still do not have any understanding of the mass caudal to the shoulder.

**SEX**

Male Neutered

**AGE**

13

**WEIGHT**

40.6

**HOSPITAL NAME**

Green Mountain  
Veterinary Hospital

**REFERRING VET**

Dr. Treat Jr.

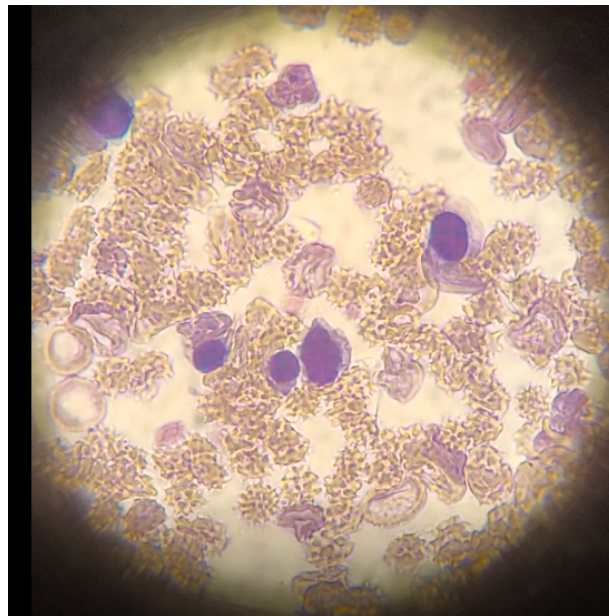


Image shows the crenated RBCs and some nucleated cells that are altered. They could be lymphocytes or NRBCs but I cannot interpret them due to artifactual change.

**INVOICE NUMBER**

803



**DATE** 9/20/22 The information and recommendations provided are based on the images presented by the referring veterinarian. No evaluation can be communicated regarding pathology that was not visible in the image/video clips provided.

**INTERPRETED BY** L.D. McGill, DVM, Ph.D., DACVP Thank you for this referral. If the clinical or image interpretation does not parallel your findings or if I can be of any further assistance please contact me.

L.D. McGill, DVM,  
Ph.D., DACVP

**L.D. McGill, DVM, Ph.D., DACVP**  
8288 Top of the World Drive  
Cottonwood Heights, UT 84121  
ldmcgill.vetpath@gmail.com  
cell: 801-865-1220

**PATIENT**

Loki Dunbar

**SPECIES**

Canine

**BREED**

Border Collie, Mixed  
Collie

**SEX**

Male Neutered

**AGE**

13

**WEIGHT**

40.6

**HOSPITAL NAME**

Green Mountain  
Veterinary Hospital

**REFERRING VET**

Dr. Treat Jr.

**INVOICE NUMBER**

803