

DATE

9/18/21

CYTOLOGY SUBMISSION

FNA of intestinal mass

INTERPRETED BY

L.D. McGill, DVM,
Ph.D, DACVP

OBSERVATIONS

Intestinal mass: Submitted are 9 excellent videos of moderate collections of cells from the intestinal mass in Griffin. Over 50% of the cells are large irregular lymphocytes. The nuclei are variable in size and shape. Nucleoli are prominent. There are moderate numbers of neutrophils and in some instances they appear to be associated with bacteria. Occasional eosinophils are identified. Small lymphocytes are scattered throughout but few in numbers. Scattered mitotic figures are observed.

PATIENT

Griffin Nolan

INTERPRETATION OF THE FINDINGS & FURTHER RECOMMENDATIONS

Intestinal mass - Consistent with high-grade lymphoma with secondary chronic suppurative inflammation and apparent bacterial infection.

SPECIES

feline

COMMENTS

The changes in this tissue support lymphoma which appears to be high-grade. The cellularity is strongly supportive of this type of process. There is secondary inflammation including neutrophils and apparent bacterial colonies. Immunophenotyping can be undertaken with these slides utilizing PCR but there is information to suggest that immunophenotyping in the cat is not as prognostic as in the dog. There are scattered eosinophils in the smear which can be associated with T-cells and commonly in the intestine in the cat the phenotype is T-cell lymphoma. There is evidence in the literature that excision of this mass will prolong the life of Griffin. The long-term prognosis is unfavorable.

BREED

DSH

SEX

Male Neutered

AGE

13 years

The information and recommendations provided are based on the images presented by the referring veterinarian. No evaluation can be communicated regarding pathology that was not visible in the image/video clips provided.

Thank you for this referral. If the clinical or image interpretation does not parallel your findings or if I can be of any further assistance please contact me.

WEIGHT

8#

L.D. McGill, DVM, Ph.D., DACVP

8288 Top of the World Drive
Cottonwood Heights, UT 84121
ldmcgill.vetpath@gmail.com
cell: 801-865-1220

HOSPITAL NAME

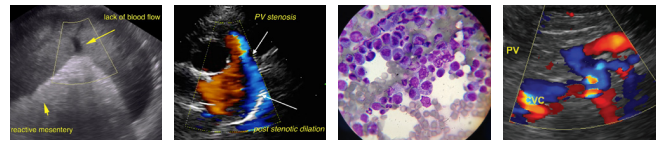
Rockaway Animal
Hospital

REFERRING VET

Dr. Maniar

INVOICE NUMBER

80296



DATE

9/18/21

INTERPRETED BY

L.D. McGill, DVM,
Ph.D, DACVP

PATIENT

Griffin Nolan

SPECIES

feline

BREED

DSH

SEX

Male Neutered

AGE

13 years

WEIGHT

8#

HOSPITAL NAME

Rockaway Animal
Hospital

REFERRING VET

Dr. Maniar

INVOICE NUMBER

80296

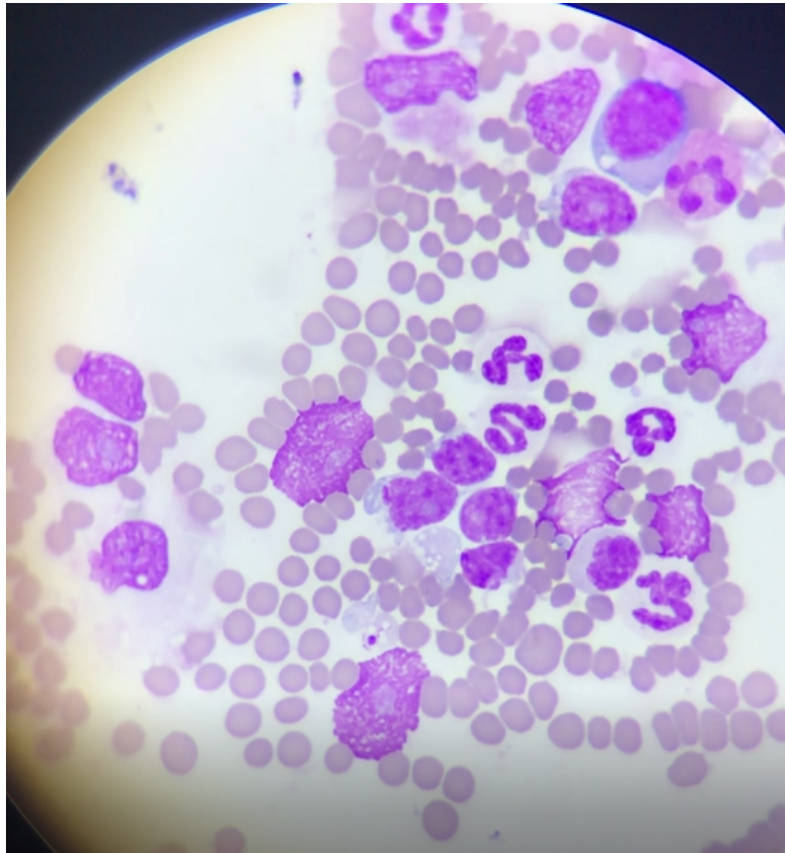


Image shows representative cells collected from the mass in Griffin. Note the large lymphocytes and the eosinophil in the upper right. The smudged nuclei suggest fragile cells common in lymphoma.