



DATE PRESENTING CLINICAL SIGNS

9/17/22

FNA of mesenteric lymph node (lymphadenopathy) and spleen (splenic enlargement).

CYTOLOGY SUBMISSION

Lymph node; spleen

INTERPRETED BY

L.D. McGill, DVM,
Ph.D, DACVP

OBSERVATIONS

Lymph node: Submitted are a large number of images and several videos collected from the mesenteric lymph nodes in Marvin. The cellularity consists of a mixture of cells with small to intermediate sized lymphocytes, neutrophils, eosinophils and macrophages. The lymphoid cells are reactive and not malignant.

PATIENT

Marvin Poulakis

Spleen: Submitted are large numbers of images and videos of cells collected from the spleen in Marvin. Many of the videos do not have any cells present. There are aggregates of platelets in several locations. Malignant characteristics are not identified. There is a mixture of cells including neutrophils, lymphocytes and nucleated red blood cells. The cellularity is not specific.

SPECIES INTERPRETATION OF THE FINDINGS & FURTHER RECOMMENDATIONS

Feline

Lymph node - Chronic suppurative and eosinophilic lymphadenitis with reactive lymphoid tissue
Spleen - Chronic suppurative splenitis with congestion and no specific change.

COMMENTS

BREED

DSH

The cellularity in the lymph node is most characteristic of a chronic inflammatory process draining to the lymph node. This could be the result of inflammation in the intestine or even in the pancreas. In a rare case, it could be the result of FIP. The changes in the spleen are secondary and not specific. There is minimal cellularity but the cells present are not specific for any process except for mild inflammation. Continued evaluation for abnormalities in the abdominal cavity is encouraged. A guarded prognosis is warranted until further information can be derived from evaluation of other organs in the abdominal cavity.

SEX

Male Neutered

AGE

2010

WEIGHT

13 lbs 15.5 oz

HOSPITAL NAME

Franklin Lakes Animal
Hospital

REFERRING VET

Dr. Hudson

INVOICE NUMBER

802

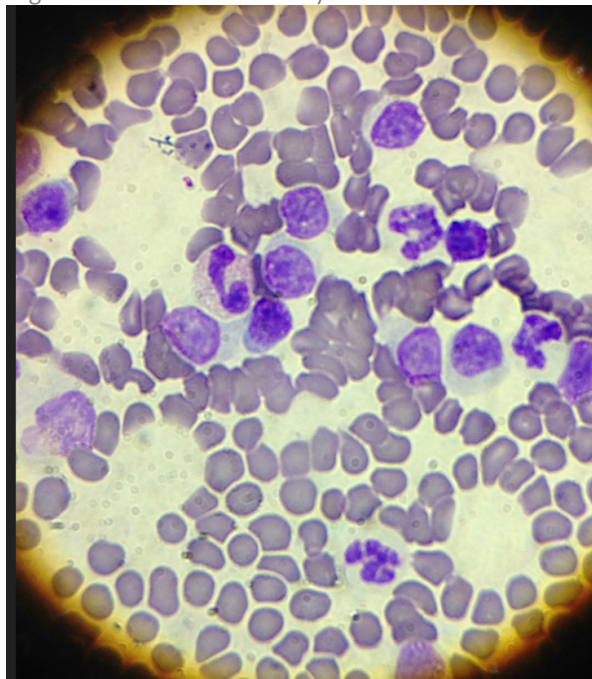


Image shows a good collection of cells from the lymph node in Marvin. Note the neutrophils and eosinophils with reactive lymphocytes.



DATE

9/17/22

INTERPRETED BY

L.D. McGill, DVM,
Ph.D, DACVP

PATIENT

Marvin Poulakis

SPECIES

Feline

BREED

DSH

SEX

Male Neutered

AGE

2010

WEIGHT

13 lbs 15.5 oz

HOSPITAL NAME

Franklin Lakes Animal
Hospital

REFERRING VET

Dr. Hudson

INVOICE NUMBER

802

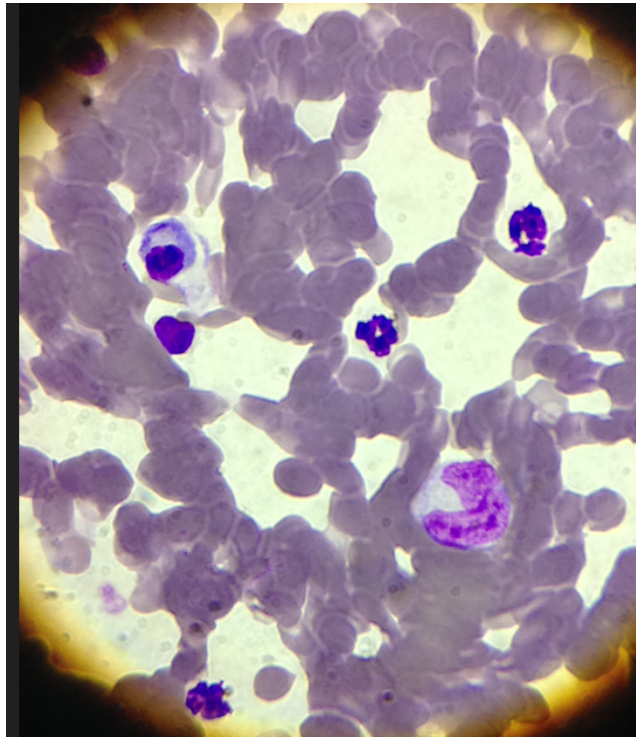


Image shows a few collections of cells from the spleen in Marvin. There are neutrophils with macrophage and a nucleated RBC. There is no suggestion of malignancy.

The information and recommendations provided are based on the images presented by the referring veterinarian. No evaluation can be communicated regarding pathology that was not visible in the image/video clips provided.

Thank you for this referral. If the clinical or image interpretation does not parallel your findings or if I can be of any further assistance please contact me.

L.D. McGill, DVM, Ph.D., DACVP
8288 Top of the World Drive
Cottonwood Heights, UT 84121
ldmcgill.vetpath@gmail.com
cell: 801-865-1220