

DATE PRESENTING CLINICAL SIGNS

9/16/22
CBC - nsf
Chem - chronic elevation in ALP supports Cushing's dz. Now his calcium is significantly elevated, concerning for either neoplasia or hyperparathyroidism.
E-lyte - wnl

INTERPRETED BY

L.D. McGill, DVM,
Ph.D, DACVP

CYTOLOGY SUBMISSION

Liver

OBSERVATIONS

Liver: Submitted are 6 excellent videos of moderate collections of cells from the liver in Chubbs. The cellularity consists of hepatocytes demonstrating vacuolization and granularity. Some of the hepatocytes are slightly irregular but the nuclear characteristics are rather uniform. Some of the fields have increased numbers of lymphocytes associated with hepatocytes. There are scattered neutrophils. Hepatocellular malignancy or sepsis cannot be identified. The lymphoid cells are increased in some fields. Several of the slides demonstrate stain precipitate or contaminated stain.

PATIENT

Chubbs Kalinowski

SPECIES

Canine

INTERPRETATION OF THE FINDINGS & FURTHER RECOMMENDATIONS

Liver - Hepatocellular vacuolization consistent with vacuolar hepatopathy and increased numbers of lymphoid cells suggesting lymphocytic inflammation or possibly early lymphoma.

BREED

Dachshund

COMMENTS

The cellularity is not specific and diagnostic for lymphoma in this case. There are some fields that suggest increased numbers of lymphoid cells causing concern about lymphoma but it is not diagnostic. There are changes supporting vacuolar hepatopathy which could be secondary to many different conditions. Lymphoma could be present in other organs and the liver be responding secondarily. Continued evaluation for other disease processes is encouraged.

SEX

Male Neutered

AGE

10y

WEIGHT

28.5 lbs

HOSPITAL NAME

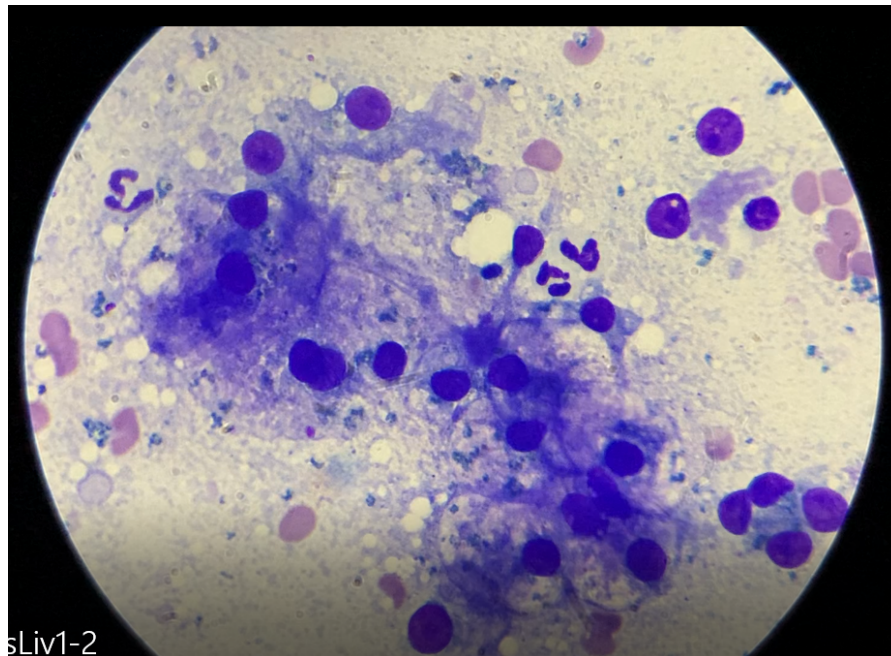
West Salem Animal
Clinic

REFERRING VET

Dr. Sirianni

INVOICE NUMBER

800



sLiv1-2

Image shows hepatocytes with vacuolization and surrounding lymphoid cells and neutrophils. The lymphoid cells are slightly varied.



DATE

9/16/22

The information and recommendations provided are based on the images presented by the referring veterinarian. No evaluation can be communicated regarding pathology that was not visible in the image/video clips provided.

INTERPRETED BY

L.D. McGill, DVM,
Ph.D., DACVP

Thank you for this referral. If the clinical or image interpretation does not parallel your findings or if I can be of any further assistance please contact me.

PATIENT

Chubbs Kalinowski

L.D. McGill, DVM, Ph.D., DACVP

8288 Top of the World Drive
Cottonwood Heights, UT 84121
ldmcgill.vetpath@gmail.com
cell: 801-865-1220

SPECIES

Canine

BREED

Dachshund

SEX

Male Neutered

AGE

10y

WEIGHT

28.5 lbs

HOSPITAL NAME

West Salem Animal
Clinic

REFERRING VET

Dr. Sirianni

INVOICE NUMBER

800