



DATE PRESENTING CLINICAL SIGNS

9/14/22

Mass noted on medial left elbow last Friday evening. Fluctuant thick mucinous exudate. Baseball sized fluctuant mass medial left elbow. Thick mucinous material (clear in nature/difficult to aspirate) aspirated.

INTERPRETED BY CYTOLOGY SUBMISSION

L.D. McGill, DVM,
Ph.D, DACVP

Synovial collection

OBSERVATIONS

Joint fluid collection: Submitted are a large number of images of cells collected from the joint region on Bluey. The cellularity consists of 1 to 2 synovial cells in several fields with a background of protein and mucus. There is no suggestion of malignancy or infection. All of the cells are reactive synovial cells.

PATIENT

Bluey Wilkinson

INTERPRETATION OF THE FINDINGS & FURTHER RECOMMENDATIONS

Joint fluid collection - Reactive synovial cells with clear joint fluid.

SPECIES COMMENTS

Feline

The cellularity is minimal and consists of very good photos of synovial cells. These are reactive synovial cells that are surrounded by synovial fluid and protein. There is no suggestion of infection or neoplasia. This type of reaction will occur in a joint that is mildly traumatized. The joint capsule apparently has ruptured allowing for the swelling that you have observed. I've seen this in several species. The cellularity is benign and non-septic and should not cause any further problems. Wrapping the joint may result in decreasing the size of this swelling.

BREED

DSH

SEX

Female Spayed

AGE

17y

WEIGHT

11.5

HOSPITAL NAME

Torch Lake Veterinary
Clinic

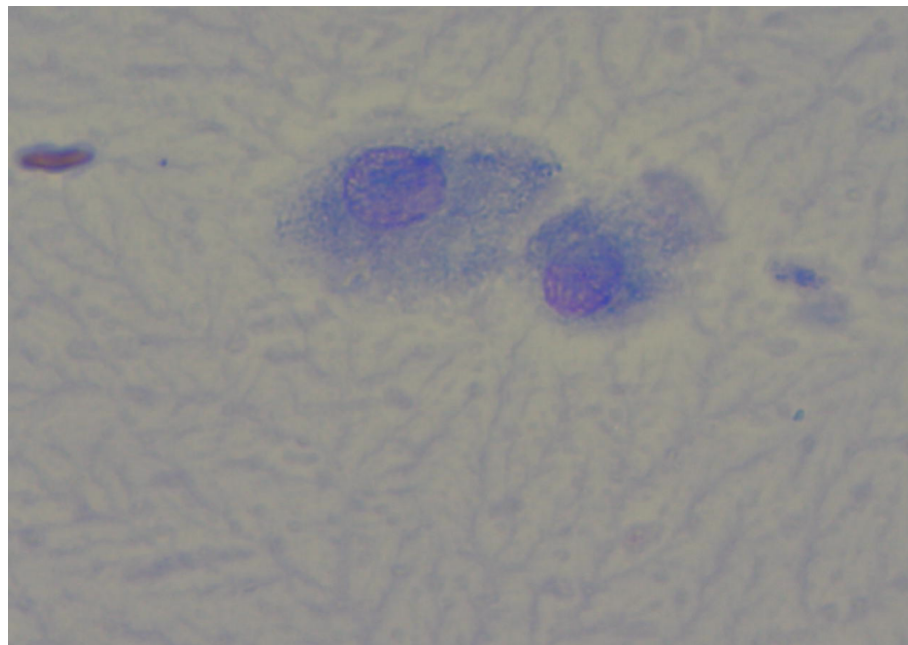


Image shows slightly reactive synovial cells surrounded by clear synovial fluid. These cells are essentially normal with mild reactivity.

REFERRING VET

Dr. Waffle

The information and recommendations provided are based on the images presented by the referring veterinarian. No evaluation can be communicated regarding pathology that was not visible in the image/video clips provided.

INVOICE NUMBER

798



DATE

9/14/22

Thank you for this referral. If the clinical or image interpretation does not parallel your findings or if I can be of any further assistance please contact me.

INTERPRETED BY

L.D. McGill, DVM,
Ph.D, DACVP

L.D. McGill, DVM, Ph.D., DACVP
8288 Top of the World Drive
Cottonwood Heights, UT 84121
ldmcgill.vetpath@gmail.com
cell: 801-865-1220

PATIENT

Bluey Wilkinson

SPECIES

Feline

BREED

DSH

SEX

Female Spayed

AGE

17y

WEIGHT

11.5

HOSPITAL NAME

Torch Lake Veterinary
Clinic

REFERRING VET

Dr. Waffle

INVOICE NUMBER

798