



**DATE PRESENTING CLINICAL SIGNS**

9/13/22

Enlarged submandibular and left prescap lymph nodes noted on annual exam 8\4\22. Samples sent to sonopath then (invoice #40575). Seen today, 9/12/22, all peripheral lymph nodes enlarged. Poor appetite over past week, now anorexic with vomiting and lethargy. Polydipsic. Severe abdominal pain. Mild anemia, Alt and AlkP elevated with abnormal Cpl.

**INTERPRETED BY**

L.D. McGill, DVM,  
Ph.D, DACVP

**CYTOLOGY SUBMISSION**

FNA of Multiple lymph nodes

**PATIENT**

Reggie Rosate

**OBSERVATIONS**

Multiple lymph nodes: Submitted are 6 excellent videos of excellent to moderate collections of cells from multiple lymph nodes in Reggie. The cellularity consists of large numbers of round cells. The round cells have prominent bluish gray cytoplasm. The nuclei are 4 to 6 times the size of red blood cells. Many of the nuclei have prominent nucleoli. Mitotic figures are readily identified. There is prominent anisocytosis and minimal anisokaryosis suggesting a very uniform cellularity.

**SPECIES**

Canine

**BREED**

Westie

**INTERPRETATION OF THE FINDINGS & FURTHER RECOMMENDATIONS**

Multiple lymph nodes - Consistent with high-grade lymphoma (see comments)

**SEX**

Male Neutered

**COMMENTS**

The cellularity in these videos is strongly consistent with a high-grade lymphoma. With the mitotic figures, the uniform cellularity and the irregular nuclear characteristics, a high-grade cellularity appears to be the most likely diagnosis. If chemotherapy is contemplated, then immunophenotyping of the cells to confirm the specific cell type may be beneficial for prognosis. The slides can be submitted for PCR testing or new slides that are not stained can be submitted for immunocytochemistry staining. Flow cytometry can be beneficial but will require a repeat collection of cells prior to submission to the laboratory. Contacting the laboratory to confirm how to submit flow cytometry samples is encouraged. An unfavorable prognosis is warranted in the long run. It is possible that with good therapy, Reggie may respond in the near term, but I would expect the long term to be unfavorable.

**AGE**

12yrs

**WEIGHT**

26.3

**HOSPITAL NAME**

Rotterdam Veterinary  
Hospital

**REFERRING VET**

Dr. Amy Scarpinato

**INVOICE NUMBER**

40601



**DATE**

9/13/22

**INTERPRETED BY**

L.D. McGill, DVM,  
Ph.D., DACVP

**PATIENT**

Reggie Rosate

**SPECIES**

Canine

**BREED**

Westie

**SEX**

Male Neutered

**AGE**

12yrs

**WEIGHT**

26.3

**HOSPITAL NAME**

Rotterdam Veterinary  
Hospital

**REFERRING VET**

Dr. Amy Scarpinato

**INVOICE NUMBER**

40601

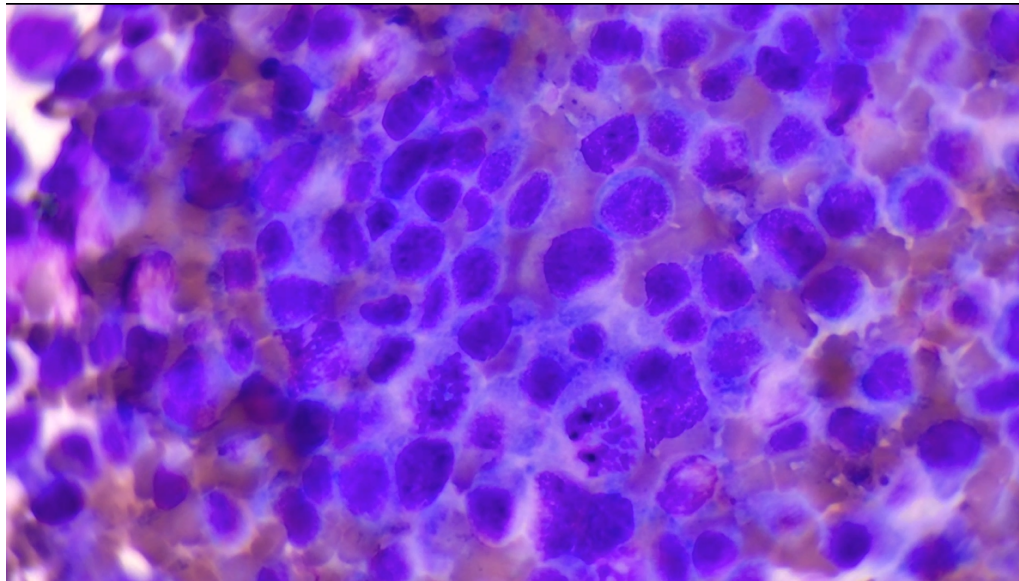


Image shows a representative collection of lymphoid cells from the lymph node in Reggie. Note the 2 mitotic figures in the center and the uniform nuclei.

The information and recommendations provided are based on the images presented by the referring veterinarian. No evaluation can be communicated regarding pathology that was not visible in the image/video clips provided.

Thank you for this referral. If the clinical or image interpretation does not parallel your findings or if I can be of any further assistance, please contact me.

**L.D. McGill, DVM, Ph.D., DACVP**  
8288 Top of the World Drive  
Cottonwood Heights, UT 84121  
ldmcgill.vetpath@gmail.com  
cell: 801-865-1220