



**DATE PRESENTING CLINICAL SIGNS**

9/10/21

Splenic nodules noted on scan from 9/2/21. FNA of largest nodule measuring 1.28 x 1.19 cm - slightly larger today at 1.20 x 1.39 cm. R/O round cell vs sarcoma vs other. Hepatic swelling noted, could be neoplastic vs benign.

**INTERPRETED BY CYTOLOGY SUBMISSION**

L.D. McGill, DVM,  
Ph.D., DACVP

FNA of Spleen

**OBSERVATIONS**

**PATIENT**

Reggie Horn

Spleen: Submitted are 6 excellent videos of excellent collections of cells from the spleen in Reggie. The majority of the cells are round cells that have characteristics of lymphocytes. The cytoplasm is minimal. The nuclei are 2 to 4 times the size of red blood cells in many lymphocytes. There are scattered plasma cells and neutrophils. Rare macrophages are identified. The lymphoid cells are the prominent cellularity with slight variation in cellular size and shape.

**SPECIES**

Canine

**INTERPRETATION OF THE FINDINGS & FURTHER RECOMMENDATIONS**

Spleen - Marked lymphoid collection suggestive of lymphoid nodular hyperplasia or possible early lymphoma.

**BREED**

Pomeranian

**COMMENTS**

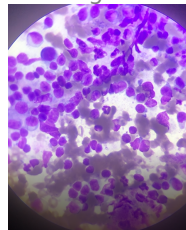
The cellularity is made up entirely of lymphoid cells with some neutrophils and rare macrophages. This can be the result of lymphoid nodular hyperplasia with a mixture of lymphoid cells. There are some irregular lymphoid cells that could suggest early lymphoma. Due to this concern, confirmation will require immunophenotyping of cells in the smears by PCR or re-collection and evaluation with flow cytometry. There are several fields that make me suspicious of lymphoma but I cannot confirm that diagnosis. Prior to chemotherapy, immunophenotyping is suggested.

**SEX**

Male Neutered

**AGE**

14 years



**WEIGHT**

N/A

Image shows a representative collection of lymphoid cells from the spleen in Reggie. Note the larger lymphoid cells.

**The information and recommendations provided are based on the images presented by the referring veterinarian. No evaluation can be communicated regarding pathology that was not visible in the image/video clips provided.**

**HOSPITAL NAME**

Newton VH

Thank you for this referral. If the clinical or image interpretation does not parallel your findings or if I can be of any further assistance please contact me.

**REFERRING VET**

Dr. Kim

**L.D. McGill, DVM, Ph.D., DACVP**

8288 Top of the World Drive  
Cottonwood Heights, UT 84121  
ldmcgill.vetpath@gmail.com  
cell: 801-865-1220

**INVOICE NUMBER**

70403



**DATE**

9/10/21

**INTERPRETED BY**

L.D. McGill, DVM,  
Ph.D, DACVP

**PATIENT**

Reggie Horn

**SPECIES**

Canine

**BREED**

Pomeranian

**SEX**

Male Neutered

**AGE**

14 years

**WEIGHT**

N/A

**HOSPITAL NAME**

Newton VH

**REFERRING VET**

Dr. Kim

**INVOICE NUMBER**

70403