



**DATE PRESENTING CLINICAL SIGNS**

8/9/22

A moveable mass of about 4-6 cm in length and 4-5 cm in diameter was observed under the ventrolateral aspect of the sternal region about 2 months ago, the mass gradually increased in size in the last month and become more visible.

**INTERPRETED BY**

L.D. McGill, DVM,  
Ph.D, DACVP

No pain on palpation and mass is moveable and FNA was performed (slide show of images under the microscope is attached)

The animal is not having any other signs and symptoms apart from an ear infection.

**CYTOLOGY SUBMISSION**

Skin mass

**PATIENT OBSERVATIONS**

Shaun Coates

Skin mass: Submitted is an image of the gross appearance of the mass and a video of several images collected from the sternal region mass on Shaun. The cellularity is very consistent throughout all of the video of the images. The cells are characteristic large cells with lipid throughout the cytoplasm and irregular vacuoles. The nuclei are slightly elongated to thin. These cells in all of the images are characteristic adipocytes.

**SPECIES**

Canine

**INTERPRETATION OF THE FINDINGS & FURTHER RECOMMENDATIONS**

Skin mass - Lipoma

**BREED COMMENTS**

Saluki Mix

The cellularity is an excellent collection of adipocytes with a very good collection of images in a video of adipocytes collected from Shaun. These cells demonstrate mature adipocyte formation. These are characteristic of the cells expected to be collected from a lipoma. Excision of this growth is expected to result in a favorable prognosis. These growths may occur in other parts of the skin and subcutis independently. Shaun should be continually monitored for independent growths. I expect a favorable prognosis after this mass is excised.

**SEX**

Male

**AGE**

11y

**WEIGHT**

21.5

**HOSPITAL NAME**

Pawsitive Veterinary  
Clinic Dubai Silicon  
Oasis

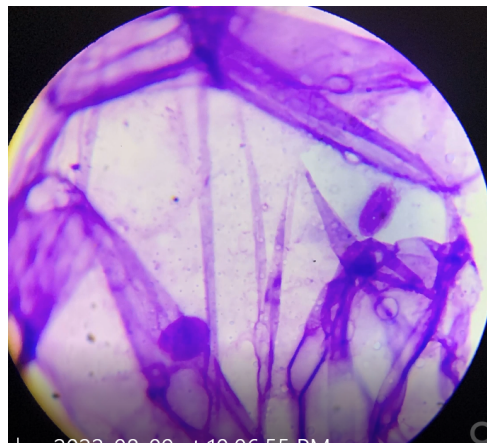


Image shows a group of mature adipocytes collected from Shaun. The nuclei are within normal limits.

**REFERRING VET**

Dr. Iftikhar Raza

The information and recommendations provided are based on the images presented by the referring veterinarian. No evaluation can be communicated regarding pathology that was not visible in the image/video clips provided.

**INVOICE NUMBER**

770



**DATE** Thank you for this referral. If the clinical or image interpretation does not parallel your findings or if I can be of any further assistance please contact me.

8/9/22

**INTERPRETED BY** L.D. McGill, DVM, Ph.D., DACVP  
8288 Top of the World Drive  
Cottonwood Heights, UT 84121  
ldmcgill.vetpath@gmail.com  
cell: 801-865-1220

**PATIENT**

Shaun Coates

**SPECIES**

Canine

**BREED**

Saluki Mix

**SEX**

Male

**AGE**

11y

**WEIGHT**

21.5

**HOSPITAL NAME**

Pawsitive Veterinary  
Clinic Dubai Silicon  
Oasis

**REFERRING VET**

Dr. Iftikhar Raza

**INVOICE NUMBER**

770