



**DATE PRESENTING CLINICAL SIGNS**

8/8/23

Presented with dyspnea. Tapped small volume pleural effusion, not enough to spin for cytospin. Straight fluid on slide.

PE: RR 50, Heart sounds muffled. BCS 5/9

RADS: Pleural effusion and possible cardiomegaly.

**INTERPRETED BY**

Pleural tap, small amount: SG 1.020, clear with some small sediment.

Echo: thickened LV walls, enlarged LA, trace pericardial effusion. Moderate pleural effusion with consolidated lung lobes. Reactive LN visible in cranial thorax.

L.D. McGill, DVM,  
Ph.D, DACVP

**PATIENT CYTOLOGY SUBMISSION**

FNA of Pleural fluid

Maple Larochelle

**OBSERVATIONS**

**SPECIES**

Pleural fluid: Submitted are 5 excellent videos of moderate collections of cells from the pleural fluid from Maple. The cellularity consists of moderate numbers of mesothelial cells with many containing foamy cytoplasm and granular material. There are scattered neutrophils. The mesothelial cells are irregular in size and shape including binucleated cells. Malignant characteristics are not identified.

Feline

**BREED**

**INTERPRETATION OF THE FINDINGS & FURTHER RECOMMENDATIONS**

DSH

Pleural fluid - Reactive mesothelial cells with mild suppurative inflammation.

**SEX**

**COMMENTS**

FS

This collection is consistent with cardiac insufficiency. There is fluid and material with minimal inflammation. There is no suggestion of malignancy or sepsis. The cellularity is consistent with chronic irritation to the pleural lining. It could also be due to leakage from the lungs. I don't have much more to add in this collection.

**AGE**

10 months

**WEIGHT**

9 lbs

**HOSPITAL NAME**

Scanvet

**REFERRING VET**

Dr. Lane

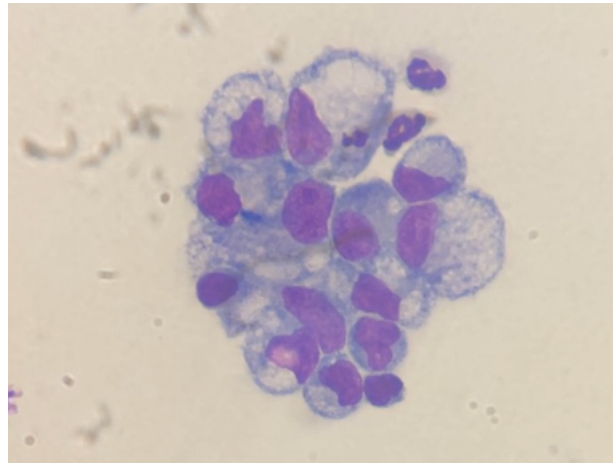


Image shows a group of mesothelial cells with foamy cytoplasm and a couple of neutrophils collected from the pleural fluid from Maple. Note the anisocytosis and anisokaryosis in the cells.

**INVOICE NUMBER**

40794



**DATE** 8/8/23 The information and recommendations provided are based on the images presented by the referring veterinarian. No evaluation can be communicated regarding pathology that was not visible in the image/video clips provided.

**INTERPRETED BY** Thank you for this referral. If the clinical or image interpretation does not parallel your findings or if I can be of any further assistance, please contact me.

L.D. McGill, DVM,  
Ph.D., DACVP

**L.D. McGill, DVM, Ph.D., DACVP**  
8288 Top of the World Drive  
Cottonwood Heights, UT 84121  
ldmcgill.vetpath@gmail.com  
cell: 801-865-1220

**PATIENT**

Maple Larochelle

**SPECIES**

Feline

**BREED**

DSH

**SEX**

FS

**AGE**

10 months

**WEIGHT**

9 lbs

**HOSPITAL NAME**

Scanvet

**REFERRING VET**

Dr. Lane

**INVOICE NUMBER**

40794