

DATE PRESENTING CLINICAL SIGNS

8/07/23

1cm x 5mm mass on left front above carpus. Owner says it comes and goes.

CYTOLOGY SUBMISSION

Cytology

INTERPRETED BY

L.D. McGill, DVM,
Ph.D, DACVP

OBSERVATIONS

Skin lesion: Submitted are 4 excellent images and 3 excellent videos of minimal numbers of cells collected from the skin lesion on Loki. The cellularity is mixed. There are spindle cells with scattered neutrophils and lymphocytes. Macrophages are interspersed in some of the fields. The spindle cells are quite prominent. They demonstrate anisocytosis and anisokaryosis but there are very few of them. Malignant characteristics are not confirmed.

SPECIES

Canine

INTERPRETATION OF THE FINDINGS & FURTHER RECOMMENDATIONS

Skin lesion - Pyogranulomatous inflammation with fibrosis.

BREED

Pug

COMMENTS

The cellularity in this collection is most consistent with some type of chronic inflammatory process. It could be the result of a foreign body penetration or an insect sting of some type with fibrosis and granulation tissue. There is an outside possibility of a spindle cell tumor with secondary inflammation but there did not appear to be adequate numbers of spindle cells to make that diagnosis. Treatment with anti-inflammatory products is encouraged but this lesion may have to be excised in the future. I was unable to identify characteristics to confirm malignancy or sepsis.

SEX

Male Neutered

AGE

9yrs

WEIGHT

18.9lbs

HOSPITAL NAME

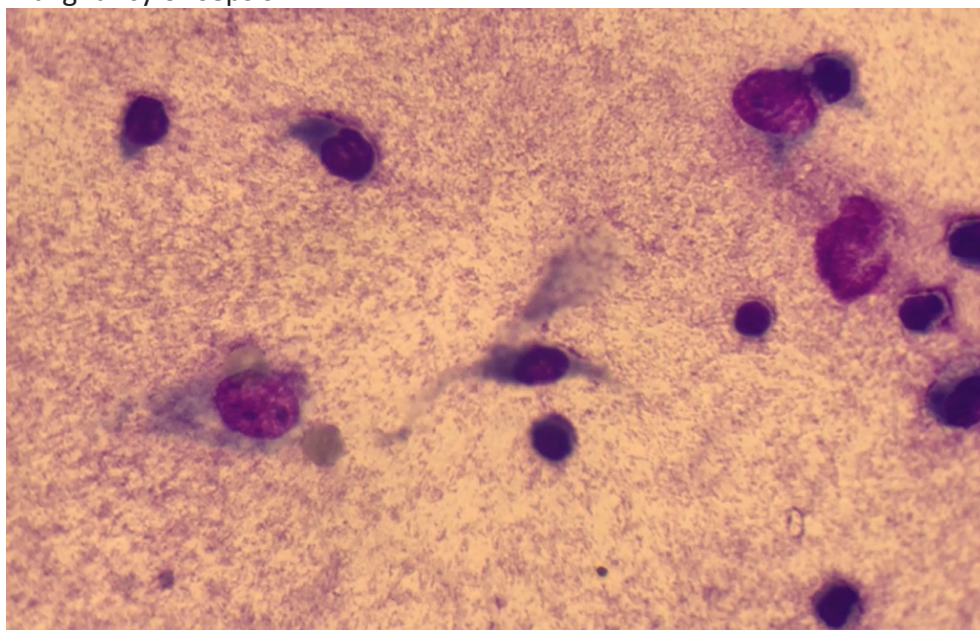
Rotterdam Veterinary
Hospital

REFERRING VET

Dr. Amy Scarpinato

INVOICE NUMBER

805





DATE 8/07/23
Image shows a mixture of cells including neutrophils, lymphocytes and spindle cells with macrophages collected from the lesion aspirated from the skin on Loki. The spindle cells are slightly irregular but do not confirm malignancy.

INTERPRETED BY
L.D. McGill, DVM, Ph.D, DACVP
The information and recommendations provided are based on the images presented by the referring veterinarian. No evaluation can be communicated regarding pathology that was not visible in the image/video clips provided.

PATIENT
Thank you for this referral. If the clinical or image interpretation does not parallel your findings or if I can be of any further assistance please contact me.

Loki Palmer

SPECIES
Canine
BREED
Pug
SEX
Male Neutered
AGE
9yrs
WEIGHT
18.9lbs

L.D. McGill, DVM, Ph.D., DACVP
8288 Top of the World Drive
Cottonwood Heights, UT 84121
ldmcgill.vetpath@gmail.com
cell: 801-865-1220

HOSPITAL NAME
Rotterdam Veterinary
Hospital

REFERRING VET
Dr. Amy Scarpinato

INVOICE NUMBER
805