



**DATE PRESENTING CLINICAL SIGNS**

8/7/23 Skin mass growing slowly for the last 2 months no other lumps in the body  
Solitary, alopecic not ulcerated cutaneous mass on the left side of the neck.  
Growing slowly for the last 2 months.  
Otherwise the patient is normal.

**INTERPRETED BY**

L.D. McGill, DVM,  
Ph.D, DACVP

**CYTOLOGY SUBMISSION**

Neck skin lesion

**OBSERVATIONS**

Neck skin lesion: Submitted are 2 excellent videos of very good collections of cells from the skin mass on Junior. The cellularity consists of large numbers of round cells with scattered neutrophils and macrophages. Many of the round cells are lymphocytes and the majority of the lymphocytes are small mature lymphocytes. There are scattered reactive lymphocytes. Some degenerate nuclear debris is present. Malignant characteristics are not confirmed.

**SPECIES INTERPRETATION OF THE FINDINGS & FURTHER RECOMMENDATIONS**

Canine

Neck skin lesion - Pyogranulomatous inflammation with large numbers of lymphocytes.

**COMMENTS**

The cellularity supports a chronic inflammatory process with some potential of an antigenic reaction. The location seems somewhat atypical but an injection site granuloma can have similar cellularity. I was unable to identify malignancy or sepsis. Continued monitoring of this reaction is encouraged. It may be the result of a foreign body penetration or an insect bite or sting. If problems continue, then excision of the mass is encouraged. A follow-up biopsy may be in order. Cytologically the cellularity is inflammatory and benign. A favorable prognosis is expected with this cellularity but the cause is unknown.

**BREED**

American Bully

**SEX**

Male

**AGE**

1y3m

**WEIGHT**

21kg

**HOSPITAL NAME**

City Veterinary Clinic

**REFERRING VET**

Dr. Inam ul haq

**INVOICE NUMBER**

985

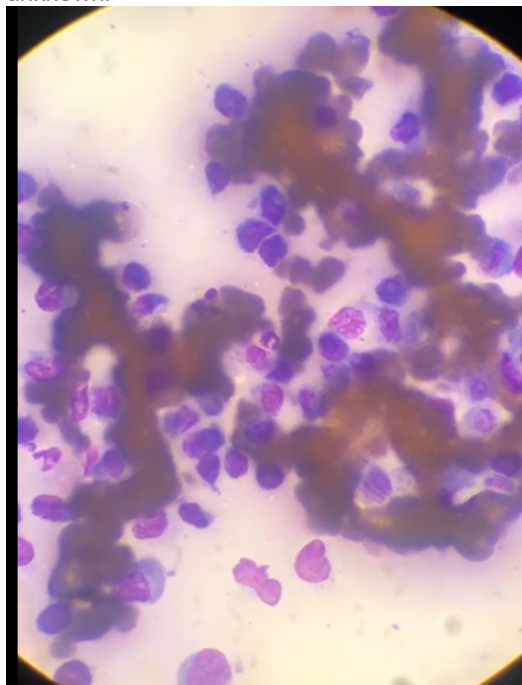


Image shows large numbers of lymphocytes interspersed with neutrophils and macrophages and red blood cells. This was collected from the neck lesion on Junior.



**DATE** 8/7/23 The information and recommendations provided are based on the images presented by the referring veterinarian. No evaluation can be communicated regarding pathology that was not visible in the image/video clips provided.

**INTERPRETED BY** L.D. McGill, DVM, Ph.D., DACVP Thank you for this referral. If the clinical or image interpretation does not parallel your findings or if I can be of any further assistance please contact me.

L.D. McGill, DVM,  
Ph.D., DACVP

**L.D. McGill, DVM, Ph.D., DACVP**  
8288 Top of the World Drive  
Cottonwood Heights, UT 84121  
ldmcgill.vetpath@gmail.com  
cell: 801-865-1220

**PATIENT**

Junior Saad

**SPECIES**

Canine

**BREED**

American Bully

**SEX**

Male

**AGE**

1y3m

**WEIGHT**

21kg

**HOSPITAL NAME**

City Veterinary Clinic

**REFERRING VET**

Dr. Inam ul haq

**INVOICE NUMBER**

985