



DATE PRESENTING CLINICAL SIGNS

8/7/23

Patient presented 8/5/23 to check a mass near the penis. Mass measures 3.75 in X 3.5 in X 3 in and is located right lateral /cranial aspect of the prepuce - approximately 1 inch from the tip of the penis.

INTERPRETED BY

L.D. McGill, DVM,
Ph.D, DACVP

Fine needle aspirate performed in-house prior to looking at slides suspected lipoma - however some concerning cells present throughout slides. All images being sent are stills because there weren't many cells present and they were greatly spaced out throughout slides. When making the slides a lot of lipid-like material was aspirated.

PATIENT CYTOLOGY SUBMISSION

Colby Traver

FNA of Dermal

SPECIES OBSERVATIONS

Canine

Abdominal mass near penis: Submitted are 24 images of material and cells collected from the mass near the penis on Colby. There is minimal hemodilution. The cells present include round cells that are macrophages with foamy cytoplasm and scattered spindle cells with some accumulation of lipid.

BREED

Spinone

Debris is present. No bacteria were identified but there is a background of protein in some locations that is clumped. There is no suggestion of malignancy or sepsis.

SEX INTERPRETATION OF THE FINDINGS & FURTHER RECOMMENDATIONS

Male Neutered

Abdominal mass near penis - Consistent with lipoma with secondary granulomatous inflammation and spindle cell proliferation.

AGE COMMENTS

10 yrs

With this very clean aspirate of minimal numbers of cells, the changes are most consistent with those of a lipoma with secondary inflammation and fibrosis. There are no cellular changes that would support malignancy or sepsis. There is some lipid and some suggestion of adipose tissue in this collection with the scattered macrophages and spindle cells that can respond to lipomas that are traumatized. Excision of the lesion is encouraged. Independent growths may occur in other sites. A favorable prognosis is expected with complete excision.

WEIGHT

106 lbs

HOSPITAL NAME

Harveys Lake Veterinary
Clinic

REFERRING VET

Dr. John Bucha VMD

INVOICE NUMBER

40792



DATE

8/7/23

INTERPRETED BY

L.D. McGill, DVM,
Ph.D, DACVP

PATIENT

Colby Traver

SPECIES

Canine

BREED

Spinone

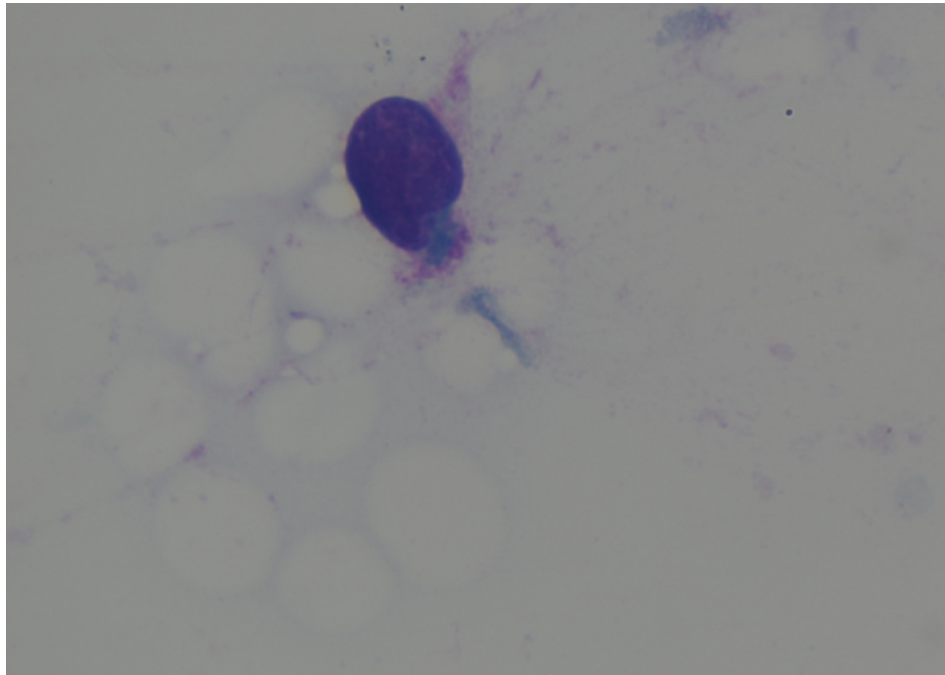


Image shows a macrophage with adipose material and lipid associated. This was collected from the abdominal mass on Colby.

SEX

Male Neutered

The information and recommendations provided are based on the images presented by the referring veterinarian. No evaluation can be communicated regarding pathology that was not visible in the image/video clips provided.

AGE

10 yrs

Thank you for this referral. If the clinical or image interpretation does not parallel your findings or if I can be of any further assistance, please contact me.

WEIGHT

106 lbs

L.D. McGill, DVM, Ph.D., DACVP
8288 Top of the World Drive
Cottonwood Heights, UT 84121
ldmcgill.vetpath@gmail.com
cell: 801-865-1220

HOSPITAL NAME

Harveys Lake Veterinary
Clinic

REFERRING VET

Dr. John Bucha VMD

INVOICE NUMBER

40792