



DATE PRESENTING CLINICAL SIGNS

8/5/22

Patient presented for routine exam 8/4/22. Upon exam, it was noted that his submandibular lymph nodes were enlarged, particularly on the left side. Left prescapular lymph node was also enlarged. Sample videos attached were taken via FNA. Patient did have dermatitis on lips and thorax on exam, sent home with antibiotics.

INTERPRETED BY

L.D. McGill, DVM,
Ph.D, DACVP

CYTOLOGY SUBMISSION

FNA of Dermal/ Lymph node

PATIENT

Reggie Rosate

OBSERVATIONS

Lymph node: Submitted are 3 videos collected from a lymph node in Reggie. One of the videos demonstrates cells that are inadequately stained and therefore the nuclei are not identifiable. The other two smears and videos have well stained cells. The majority of the cells are small to intermediate size lymphocytes with scattered neutrophils and even scattered eosinophils. Scattered macrophages are present. Malignant characteristics are not identified.

SPECIES

Canine

BREED

West Highland Terrier

INTERPRETATION OF THE FINDINGS & FURTHER RECOMMENDATIONS

Lymph node - Chronic suppurative lymphadenitis with markedly reactive or stimulated lymphoid tissue. (see comments)

SEX

Male Neutered

COMMENTS

The lymphoid tissue demonstrates reactive lymphoid tissue with evidence of inflammation draining to the node. I suspect that this node is from the submandibular region. The submandibular lymph node will demonstrate reactivity more than all of the other nodes in the body. They are draining inflammation from the head, neck and the skin. Even if this is not a submandibular lymph node, malignant characteristics are not identified. This lymph node tissue supports chronic inflammation. Continued monitoring of the nodes is encouraged. If problems continue, then repeat collection from other lymph nodes away from the submandibular region may be beneficial. A guarded prognosis is warranted.

AGE

12Y

WEIGHT

26.2#

HOSPITAL NAME

Rotterdam Veterinary
Hospital

REFERRING VET

Dr. Amy Scarpinato

INVOICE NUMBER

40575



DATE

8/5/22

INTERPRETED BY

L.D. McGill, DVM,
Ph.D, DACVP

PATIENT

Reggie Rosate

SPECIES

Canine

BREED

West Highland Terrier

SEX

Male Neutered

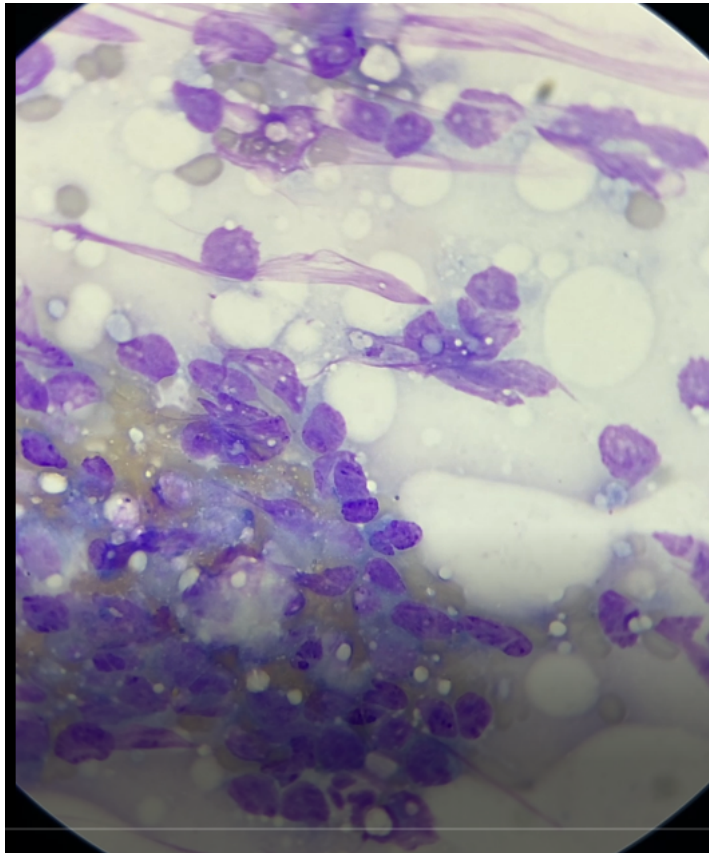


Image shows cells collected from the lymph node on Reggie. There are macrophages with a neutrophil in this collection and reactive lymphoid tissue.

AGE

12Y

The information and recommendations provided are based on the images presented by the referring veterinarian. No evaluation can be communicated regarding pathology that was not visible in the image/video clips provided.

WEIGHT

26.2#

Thank you for this referral. If the clinical or image interpretation does not parallel your findings or if I can be of any further assistance, please contact me.

HOSPITAL NAME

Rotterdam Veterinary
Hospital

L.D. McGill, DVM, Ph.D., DACVP
8288 Top of the World Drive
Cottonwood Heights, UT 84121
ldmcgill.vetpath@gmail.com
cell: 801-865-1220

REFERRING VET

Dr. Amy Scarpinato

INVOICE NUMBER

40575