



**DATE PRESENTING CLINICAL SIGNS**

8/5/22

Indoor/outdoor cat, UTD on vaccines. Urinated out of box on owner 2 days ago. P has been normal since. Normal BM. Eating/drinking well. No V/D/C/S. Normal energy.

**INTERPRETED BY**

L.D. McGill, DVM,  
Ph.D, DACVP

Mild peripheral lymphadenopathy, otherwise normal PE and vitals. UA- WNL. CBC- mild neutrophilia (10.81 K/uL) and lymphocytosis (8.19 k/uL). Mild thrombocytosis (7-8 platelets/hpf). FeLV/FIV test-negative x3.

**CYTOLOGY SUBMISSION**

Lymph node

**OBSERVATIONS**

**PATIENT**

Bro Kimbrell

Lymph node: Submitted are 3 excellent videos and 5 images of cells collected from the prescapular lymph node in Bro. The cellularity consists almost entirely of round cells that have the appearance of lymphocytes. Many of the cells are enlarged. Approximately 50% of the cells are enlarged with large nuclei that have prominent nucleoli. There are a few small lymphocytes scattered throughout. Some fields include smudged lymphoid cells and small cells but there are adequate fields to suggest early lymphoma.

**SPECIES**

Feline

**INTERPRETATION OF THE FINDINGS & FURTHER RECOMMENDATIONS**

Lymph node - Large numbers of lymphoid cells with cells suggestive of early high-grade lymphoma.

**BREED**

DSH

**COMMENTS**

The cellularity has not effaced the normal structure of this lymph node. There are adequate numbers of large cells to suggest the possibility of lymphoma. There is mild inflammation with the very rare neutrophils and macrophages. Confirmation of the diagnosis will require a follow-up biopsy or immunophenotyping of cells collected from the lymph node. I am concerned about the possibility of lymphoma but cannot confirm the diagnosis with the mixture of cells in this collection.

**SEX**

Male Neutered

**AGE**

10M

**WEIGHT**

9.8 lbs

**HOSPITAL NAME**

Ruidoso Animal Clinic

**REFERRING VET**

Dr. Thurston

**INVOICE NUMBER**

769

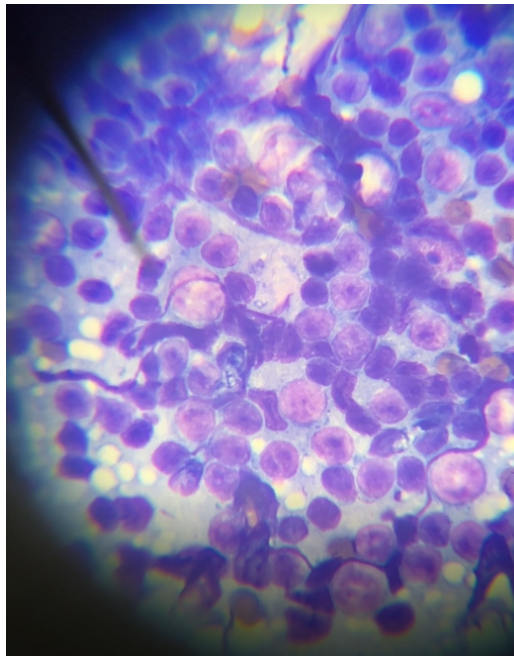


Image shows a representative collection of cells from the prescapular lymph node on Bro. Note the approximately 50% of large cells.



**DATE**

8/5/22

The information and recommendations provided are based on the images presented by the referring veterinarian. No evaluation can be communicated regarding pathology that was not visible in the image/video clips provided.

**INTERPRETED BY**

L.D. McGill, DVM,  
Ph.D, DACVP

Thank you for this referral. If the clinical or image interpretation does not parallel your findings or if I can be of any further assistance please contact me.

**PATIENT**

Bro Kimbrell

**L.D. McGill, DVM, Ph.D., DACVP**  
8288 Top of the World Drive  
Cottonwood Heights, UT 84121  
ldmcgill.vetpath@gmail.com  
cell: 801-865-1220

**SPECIES**

Feline

**BREED**

DSH

**SEX**

Male Neutered

**AGE**

10M

**WEIGHT**

9.8 lbs

**HOSPITAL NAME**

Ruidoso Animal Clinic

**REFERRING VET**

Dr. Thurston

**INVOICE NUMBER**

769