



DATE PRESENTING CLINICAL SIGNS

8/4/23

Elevated liver enzymes. On ultrasound liver is enlarged, hyperechoic and coarse.

CYTOLOGY SUBMISSION

Liver

INTERPRETED BY

L.D. McGill, DVM,
Ph.D, DACVP

OBSERVATIONS

Liver: Submitted are 9 excellent videos of excellent collections of cells from the liver in Abby. The cellularity includes large numbers of hepatocytes. The hepatocytes are rather uniform with uniform nuclei. There is prominent vacuolization of many of the hepatocytes which includes lipid. Interspersed are scattered inflammatory cells including lymphocytes and neutrophils. Malignant characteristics are not identified.

PATIENT

Abby Perkins

INTERPRETATION OF THE FINDINGS & FURTHER RECOMMENDATIONS

Liver - Mild to moderate hepatocellular lipodosis with mild chronic inflammation.

SPECIES COMMENTS

Feline

The changes in this collection suggest early feline fatty liver syndrome with lipodosis in many of the cells. There is evidence of mild inflammation. There are no suggestions of malignancy. The lipodosis with inflammation suggests the possibility of an inflammatory process draining to the liver. This can often be associated with pancreatitis. Inflammation will ascend up the biliary tree or in the bloodstream. Lipodosis often occurs secondarily. There is no suggestion of malignancy or sepsis. Treatment for inflammation and evaluation for pancreatitis is encouraged. A guarded prognosis is warranted since the liver is likely responding secondarily and not primarily.

BREED

DSH

SEX

Female Spayed

AGE

6y

WEIGHT

11.5

HOSPITAL NAME

Rotterdam Veterinary
Hospital

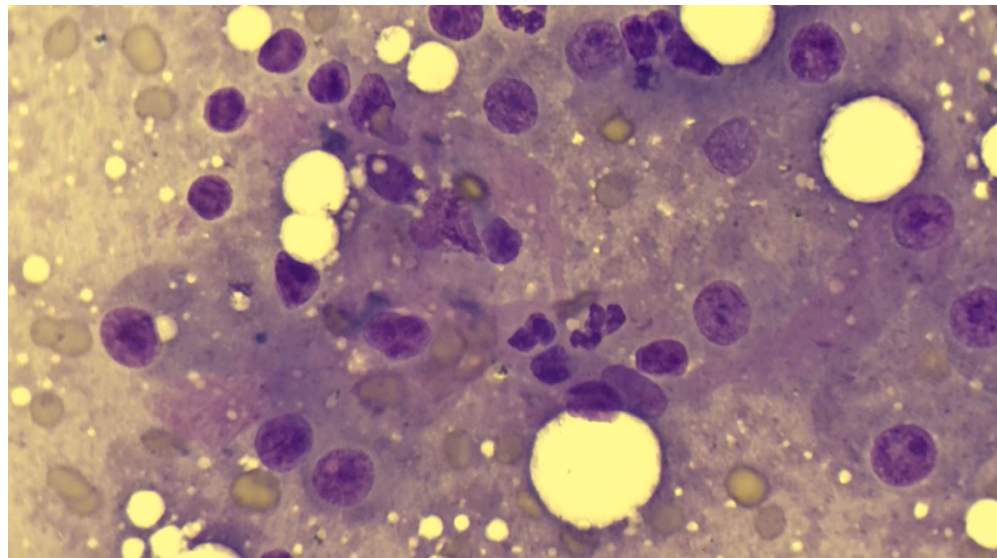


Image shows a group of hepatocytes with lipid vacuoles interspersed with neutrophils and surrounded by a few lymphocytes collected from the liver in Abby. The hepatocytes are rather uniform in nuclear patterns.

REFERRING VET

Dr. St. Sir

The information and recommendations provided are based on the images presented by the referring veterinarian. No evaluation can be communicated regarding pathology that was not visible in the image/video clips provided.

INVOICE NUMBER

984



DATE Thank you for this referral. If the clinical or image interpretation does not parallel your findings or if I can be of any further assistance please contact me.

8/4/23

INTERPRETED BY L.D. McGill, DVM, Ph.D., DACVP
8288 Top of the World Drive
Cottonwood Heights, UT 84121
ldmcgill.vetpath@gmail.com
cell: 801-865-1220

PATIENT

Abby Perkins

SPECIES

Feline

BREED

DSH

SEX

Female Spayed

AGE

6y

WEIGHT

11.5

HOSPITAL NAME

Rotterdam Veterinary
Hospital

REFERRING VET

Dr. St. Sir

INVOICE NUMBER

984