



DATE PRESENTING CLINICAL SIGNS

8/3/22

Chronic diarrhea , diabetic with poor control (periods of hypoglycemia and hyperglycemia) On abd. U/S : enlarged hypoechoic pancreas, heteroechoic mass in the R caudal liver lobe (2.9 cm diameter).

INTERPRETED BY

L.D. McGill, DVM,
Ph.D, DACVP

CYTOLOGY SUBMISSION

FNA liver mass

PATIENT

Brabinger Markley

INTERPRETATION OF THE FINDINGS & FURTHER RECOMMENDATIONS

Liver - A small number of cells suggestive of a possible mast cell tumor or chronic inflammation in a vacuolated liver.

SPECIES COMMENTS

Feline

The cellularity in this collection demonstrates a minimal number of cells but they are round cells some of which have the appearance of mast cells. This could be a mast cell tumor in the liver. There are also cells that suggest macrophages. This could be due to a chronic inflammatory process or degenerative change in the liver. With chronic pancreatitis, hepatocellular degeneration and vacuolization is common. The changes in these very few cellular images suggest the possibility of a mast cell tumor, but further diagnosis will require additional collections and images or follow-up liver biopsies to confirm the diagnosis. If this is a mast cell tumor, the spleen is likely involved as well. A guarded prognosis is warranted with these cytologic findings.

BREED

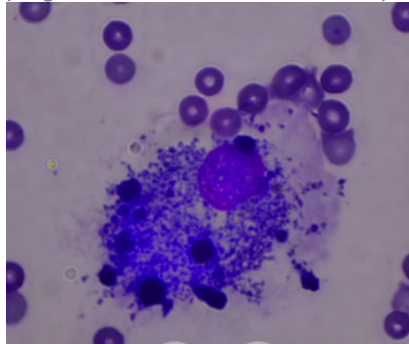
dsh

SEX

Male Neutered

AGE

15y



WEIGHT

8.1

Image shows a probable mast cell collected from the liver in Brabinger. Other cells were also suggestive of this cellularity in the few cells evaluated.

HOSPITAL NAME

Central Veterinary
Hospital

The information and recommendations provided are based on the images presented by the referring veterinarian. No evaluation can be communicated regarding pathology that was not visible in the image/video clips provided.

Thank you for this referral. If the clinical or image interpretation does not parallel your findings or if I can be of any further assistance, please contact me.

REFERRING VET

Dr. Anna St. Sir

L.D. McGill, DVM, Ph.D., DACVP
8288 Top of the World Drive
Cottonwood Heights, UT 84121
ldmcgill.vetpath@gmail.com
cell: 801-865-1220

INVOICE NUMBER

40572



DATE

8/3/22

INTERPRETED BY

L.D. McGill, DVM,
Ph.D, DACVP

PATIENT

Brabinger Markley

SPECIES

Feline

BREED

dsh

SEX

Male Neutered

AGE

15y

WEIGHT

8.1

HOSPITAL NAME

Central Veterinary
Hospital

REFERRING VET

Dr. Anna St. Sir

INVOICE NUMBER

40572