



DATE PRESENTING CLINICAL SIGNS

8/27/21 Overweight, low energy, loose stools. Vomits when not on Prednisolone, for IBD/triaditis. Elevated ALT prior to starting on Pred-L (on 0.5mg/kg EOD) PE: BCS 7/9

INTERPRETED BY

L.D. McGill, DVM, Ph.D, DACVP

BW: Cobalamin and Folate low. ALT 400 H, T-4 ranges from 4 - 4.8. Elevated amylase, Abnormal fPLI. RADS: WNL, large amount intra-abdominal fat. AUS: subjective liver enlargement, homogenous texture.

CYTOLOGY SUBMISSION

PATIENT

FNA of Liver

Kingston Stone

OBSERVATIONS

Submitted are 13 videos of cells collected from the liver in Kingston. Almost all of the videos have good collections of hepatocytes. The hepatocytes demonstrate granularity and slight vacuolization of the cytoplasm. The cytoplasm includes lipid vacuoles in a few cells. The major change observed cytologically are increased numbers of associated cells many of which are lymphocytes and neutrophils. There are scattered eosinophils. Malignant characteristics are not confirmed.

SPECIES

Feline

BREED

INTERPRETATION OF THE FINDINGS & FURTHER RECOMMENDATIONS

Liver - Chronic lymphocytic and suppurative inflammation with early hepatic lipidosis.

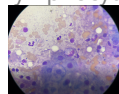
DSH

COMMENTS

The changes in this liver collection suggest chronic inflammation and a probable lymphocytic and suppurative cholangiohepatitis. Eosinophils are present and could be a secondary change or primary change in the liver in the cat. Malignant characteristics are not identified in the lymphocytes but this could be a very early lymphoma. A follow-up biopsy of the liver may be required to suggest or confirm that diagnosis. At this time I am concerned about a chronic lymphocytic and suppurative cholangiohepatitis or diffuse hepatitis which hopefully will respond to therapy. There are more lymphocytes and neutrophils than would be expected in the normal cat liver.

AGE

11 years



WEIGHT

Image shows a representative inflammatory reaction with hepatocytes in the liver in Kingston. Note the neutrophils and lymphocytes and an eosinophil in the upper right.

19lb 3 oz

The information and recommendations provided are based on the images presented by the referring veterinarian. No evaluation can be communicated regarding pathology that was not visible in the image/video clips provided.

HOSPITAL NAME

Scanvet

Thank you for this referral. If the clinical or image interpretation does not parallel your findings or if I can be of any further assistance please contact me.

REFERRING VET

Dr. Bennett

L.D. McGill, DVM, Ph.D., DACVP

8288 Top of the World Drive
Cottonwood Heights, UT 84121
ldmcgill.vetpath@gmail.com
cell: 801-865-1220

INVOICE NUMBER

70399



DATE

8/27/21

INTERPRETED BY

L.D. McGill, DVM,
Ph.D., DACVP

PATIENT

Kingston Stone

SPECIES

Feline

BREED

DSH

SEX

FS

AGE

11 years

WEIGHT

19lb 3 oz

HOSPITAL NAME

Scanvet

REFERRING VET

Dr. Bennett

INVOICE NUMBER

70399