

**DATE** **PRESENTING CLINICAL SIGNS**  
8/24/22 Presented for diarrhea  
Brief RAU view showed lung mass.

**INTERPRETED BY** **CYTOLOGY SUBMISSION**  
L.D. McGill, DVM, Ph.D, DACVP Anterior thoracic mass

**PATIENT** **OBSERVATIONS**  
Millie Saleen Anterior thoracic mass: Submitted are 6 excellent videos of excellent collections of cells from this anterior thoracic mass in Millie. The cellularity in general consists of a collection of round cells. The majority of the round cells are small mature lymphocytes. There are few reactive lymphocytes. In a few fields, there are some collections of slightly larger cells that are somewhat different from lymphocytes. These cells are irregular in the collections. Some of these cells have nucleoli. Malignant characteristics are difficult to identify.

**SPECIES** **INTERPRETATION OF THE FINDINGS & FURTHER RECOMMENDATIONS**  
Canine Anterior thoracic mass - Lymphocytic cellular collection with a few large cells suggestive of a thymoma.

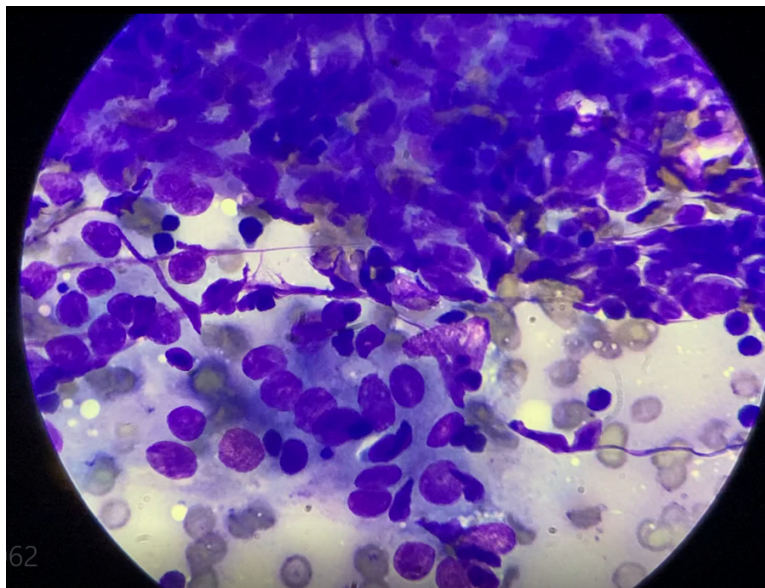
**BREED** **COMMENTS**  
Beagle X The cellularity with the small lymphocytes and the larger irregular cells that may be epithelial cells strongly suggest the likelihood of a thymoma. Further confirmation of the cell type may be beneficial. This may require immunophenotyping of the cells. Excision of the mass may be beneficial in at least prolonging the life in Millie. A guarded prognosis is warranted due to the cellularity present and concern as to how Millie may respond to therapy.

**SEX**  
Female Spayed

**AGE**  
15y

**WEIGHT**  
31 lbs

**HOSPITAL NAME**  
Companion Pet Clinic



**REFERRING VET** Image demonstrates a large number of small lymphocytes with larger cells in the lower part of the image collected from the anterior thoracic mass in Millie. Further evaluation is in order.  
Dr. Mills

**INVOICE NUMBER**  
783



**DATE** 8/24/22 **The information and recommendations provided are based on the images presented by the referring veterinarian. No evaluation can be communicated regarding pathology that was not visible in the image/video clips provided.**

**INTERPRETED BY** L.D. McGill, DVM, Ph.D., DACVP **Thank you for this referral. If the clinical or image interpretation does not parallel your findings or if I can be of any further assistance please contact me.**

L.D. McGill, DVM,  
Ph.D., DACVP

**L.D. McGill, DVM, Ph.D., DACVP**  
8288 Top of the World Drive  
Cottonwood Heights, UT 84121  
ldmcgill.vetpath@gmail.com  
cell: 801-865-1220

**PATIENT**  
Millie Saleen

**SPECIES**

Canine

**BREED**

Beagle X

**SEX**

Female Spayed

**AGE**

15y

**WEIGHT**

31 lbs

**HOSPITAL NAME**

Companion Pet Clinic

**REFERRING VET**

Dr. Mills

**INVOICE NUMBER**

783