



DATE PRESENTING CLINICAL SIGNS

8/23/22

Patient presented for Annual Exam 8/23/22 with new mass on right lateral thorax. Subcutaneous, somewhat firm, somewhat mobile. 5.1X5.3cm in size.

INTERPRETED BY CYTOLOGY SUBMISSION

L.D. McGill, DVM,
Ph.D, DACVP

FNA of Dermal - Lateral thoracic mass

PATIENT

Bailey Newcomb

OBSERVATIONS

Lateral thoracic mass: Submitted are 3 excellent videos of minimal collections of cells from the lateral thoracic mass on Bailey. The cellularity includes some spindle to polypoidal cells with scattered neutrophils, macrophages and some apparent blood clot. There is some lipid. Malignant characteristics are not identified.

SPECIES

Canine

INTERPRETATION OF THE FINDINGS & FURTHER RECOMMENDATIONS

Lateral thoracic mass - Minimal cellularity with spindle cells and probable macrophages with neutrophils.

BREED

Labrador Retriever

COMMENTS

This cellularity may not represent the major process. This may be a pyogranulomatous reaction with fibrosis, or it may be a soft tissue sarcoma. Some of these low grade growths do not release cells readily. Granulation tissue may be hard to collect also. I cannot confirm malignancy or infection. A follow up biopsy will be necessary to confirm the process or a repeat aspirate with the goal of collecting more cells may be necessary. There is at least some inflammation and possibly hemorrhage here.

SEX

FS

AGE

8y

WEIGHT

92.7#

HOSPITAL NAME

Rotterdam Veterinary
Hospital

REFERRING VET

Dr. Amy Scarpinato

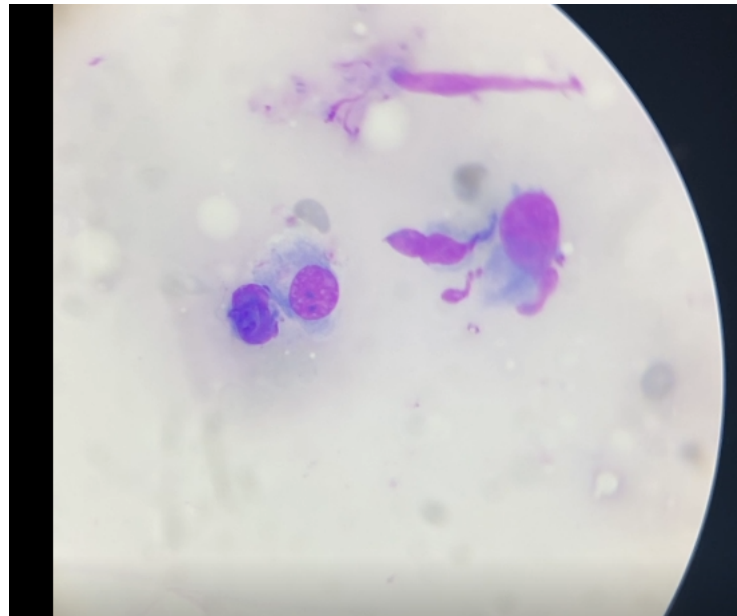


Image shows a few of the cells collected from the subcutaneous mass on Bailey. They suggest spindle to polyhedral cells.

INVOICE NUMBER

40584



DATE 8/23/22 The information and recommendations provided are based on the images presented by the referring veterinarian. No evaluation can be communicated regarding pathology that was not visible in the image/video clips provided.

INTERPRETED BY L.D. McGill, DVM, Ph.D., DACVP Thank you for this referral. If the clinical or image interpretation does not parallel your findings or if I can be of any further assistance, please contact me.

L.D. McGill, DVM,
Ph.D., DACVP

L.D. McGill, DVM, Ph.D., DACVP
8288 Top of the World Drive
Cottonwood Heights, UT 84121
ldmcgill.vetpath@gmail.com
cell: 801-865-1220

PATIENT Bailey Newcomb

SPECIES

Canine

BREED

Labrador Retriever

SEX

FS

AGE

8y

WEIGHT

92.7#

HOSPITAL NAME

Rotterdam Veterinary
Hospital

REFERRING VET

Dr. Amy Scarpinato

INVOICE NUMBER

40584