



DATE PRESENTING CLINICAL SIGNS

8/22/23

Increased liver enz, icteric, o reports was not eating 3-4 days, chronic wt loss ~4 months. No current meds. Liver FNA.
BUN 12, Globulin 5.2, ALT 565, Alk Phos 155, TBili 3.4, GGT normal

INTERPRETED BY CYTOLOGY SUBMISSION

L.D. McGill, DVM,
Ph.D, DACVP

Liver

OBSERVATIONS

Liver: Submitted are 12 excellent videos of cells collected from the liver in Boo. The cellularity consists of a mixture of erythrocytes with inflammatory cells that are neutrophils, lymphocytes and rare macrophages. There are good collections of hepatocytes. The hepatocytes demonstrate vacuolization and lipid in relation. There is no suggestion of infiltration of cells or malignancy in the collection.

PATIENT

Boo Bredefeld

INTERPRETATION OF THE FINDINGS & FURTHER RECOMMENDATIONS

Liver - Hepatocellular vacuolization consistent with feline fatty liver syndrome with secondary chronic suppurative inflammation.

SPECIES

Feline

COMMENTS

The cellularity supports a chronic inflammatory process in this collection. The inflammatory process is also associated with hepatocellular vacuolization and apparent lipidosis. The lipidosis is likely secondary to the anorexia that you have described clinically. The inflammation and lipidosis could easily be secondary to chronic pancreatitis in Boo. Continued evaluation for pancreatitis or other sources of chronic inflammation and endotoxic processes draining to the liver in Boo is suggested. A guarded prognosis is warranted since the underlying process is not identified in this liver and is likely responding secondarily.

BREED

DSH

SEX

Male Neutered

AGE

13y

WEIGHT

8.75#

HOSPITAL NAME

The Gentle Vet

REFERRING VET

Dr. Dulude

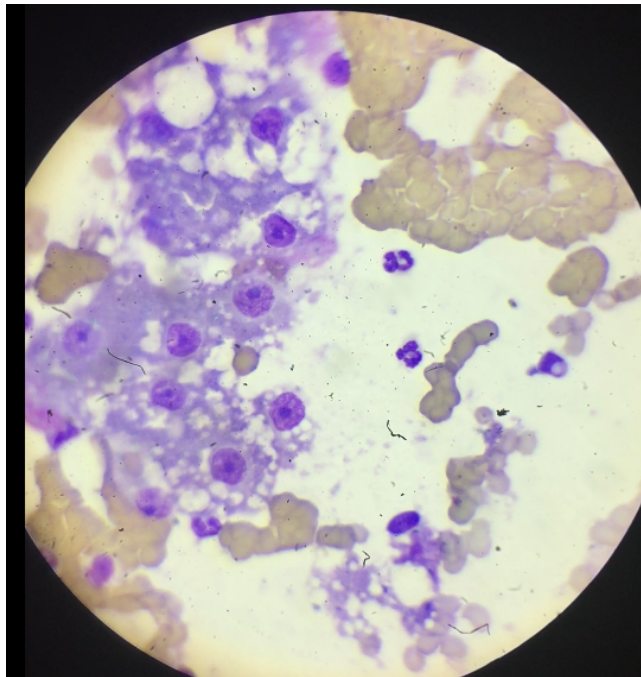


Image demonstrates hepatocellular vacuolization and a mixture of inflammatory cells collected from the liver aspirate in Boo. The inflammatory cells are mainly neutrophils.

INVOICE NUMBER

990



DATE 8/22/23 The information and recommendations provided are based on the images presented by the referring veterinarian. No evaluation can be communicated regarding pathology that was not visible in the image/video clips provided.

INTERPRETED BY L.D. McGill, DVM, Ph.D., DACVP Thank you for this referral. If the clinical or image interpretation does not parallel your findings or if I can be of any further assistance please contact me.

L.D. McGill, DVM,
Ph.D., DACVP

L.D. McGill, DVM, Ph.D., DACVP
8288 Top of the World Drive
Cottonwood Heights, UT 84121
ldmcgill.vetpath@gmail.com
cell: 801-865-1220

PATIENT

Boo Bredefeld

SPECIES

Feline

BREED

DSH

SEX

Male Neutered

AGE

13y

WEIGHT

8.75#

HOSPITAL NAME

The Gentle Vet

REFERRING VET

Dr. Dulude

INVOICE NUMBER

990