



DATE **PRESENTING CLINICAL SIGNS**
8-22-21 anorexia, some vomiting. US showed liver with cholangiohepatitis pattern, R/O emerging hepatic lymphoma.

INTERPRETED BY **CYTOLOGY SUBMISSION**
L.D. McGill, DVM,
Ph.D., DACVP FNA of liver performed.

PATIENT **OBSERVATIONS**
Oscar Moser Liver: Submitted are 6 excellent videos of excellent collections of hepatocytes with inflammatory cells collected from Oscar. There are good collections of hepatocytes with slight granularity and vacuolization of the cytoplasm. There are moderate numbers of lymphocytes with scattered neutrophils in the surrounding areas. There are no characteristics of neoplasia. The lymphocytes are mature small lymphocytes.

SPECIES **INTERPRETATION OF THE FINDINGS & FURTHER RECOMMENDATIONS**
feline Liver - Suggestive of lymphocytic and mild suppurative hepatitis.

BREED **COMMENTS**
DSH The cellularity is not characteristic of neoplasia. The changes support chronic inflammation with prominent lymphocytes and scattered neutrophils. This suggests lymphocytic cholangiohepatitis. The neutrophils support inflammation. These changes support an inflammatory hepatopathy with nonspecific inflammation. This change is possibly due to ascending inflammation. Treatment for inflammation is encouraged.
SEX
Male Neutered

AGE **The information and recommendations provided are based on the images presented by the referring veterinarian. No evaluation can be communicated regarding pathology that was not visible in the image/video clips provided.**
13 years

WEIGHT Thank you for this referral. If the clinical or image interpretation does not parallel your findings or if I can be of any further assistance please contact me.

6.9#
L.D. McGill, DVM, Ph.D., DACVP
8288 Top of the World Drive
Cottonwood Heights, UT 84121
ldmcgill.vetpath@gmail.com
cell: 801-865-1220

HOSPITAL NAME
Rockaway Animal
Hospital

REFERRING VET
Dr. Ascot

INVOICE NUMBER
80292



DATE

8-22-21

INTERPRETED BY

L.D. McGill, DVM,
Ph.D, DACVP

PATIENT

Oscar Moser

SPECIES

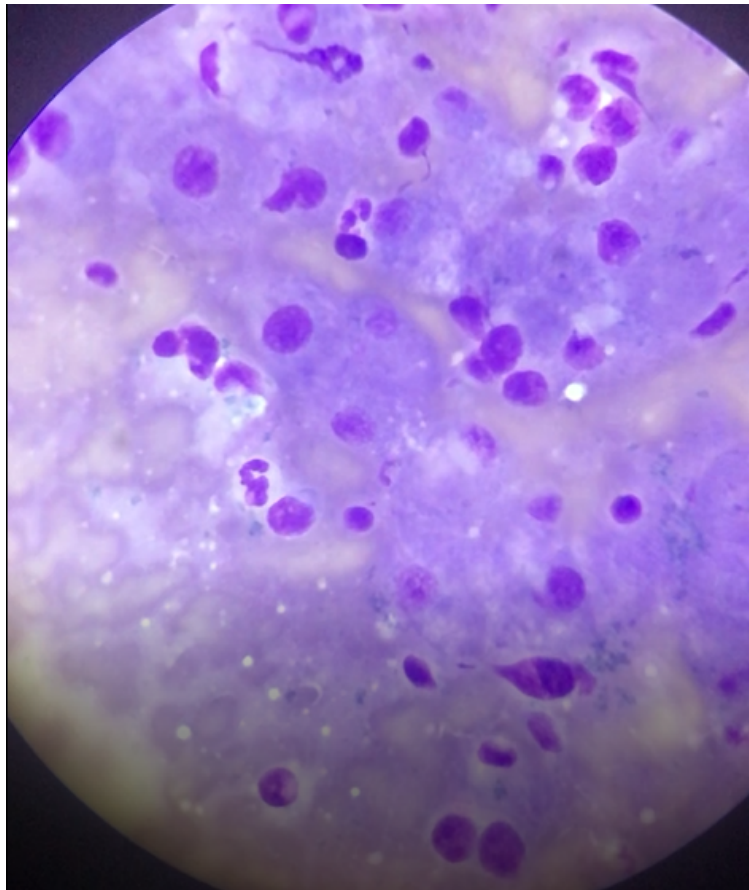
feline

BREED

DSH

SEX

Male Neutered



AGE

13 years

WEIGHT

6.9#

HOSPITAL NAME

Rockaway Animal
Hospital

REFERRING VET

Dr. Ascot

INVOICE NUMBER

80292

Image shows hepatocytes with interspersed lymphocytes and neutrophils. Neoplastic changes are not identified.