



DATE PRESENTING CLINICAL SIGNS

8/2/23

normal DUDE
no CSVD
there is mass around 4-3 cm start to grow for the last 3 weeks
and this mass under the skin under the right flank area

INTERPRETED BY

L.D. McGill, DVM,
Ph.D, DACVP

CYTOLOGY SUBMISSION

FNA Right Flank Mass

PATIENT

Asma East Farm

OBSERVATIONS

Right flank mass: Submitted is 1 excellent video and 5 excellent images of cells collected from the right flank mass on Asma. The cellularity is mixed. There are prominent neutrophils with scattered lymphocytes and eosinophils. Reactive macrophages are present but few. Malignant characteristics are not identified.

SPECIES

Canine

INTERPRETATION OF THE FINDINGS & FURTHER RECOMMENDATIONS

Right flank mass - Pyogranulomatous inflammation with scattered eosinophils.

BREED

saluki

COMMENTS

The cellularity is a characteristic inflammatory process. I have seen this type of reaction with injection site granulomas. It could be a foreign body granuloma with inflammation or a ruptured keratinized cyst. This is an inflammatory reaction with no suggestion of neoplasia in these images or video. Treatment for inflammation is encouraged. If there is a history of an injection at this location, then monitoring the site is in order. If it continues to enlarge, then excision with a follow-up biopsy may be required. An outside possibility is a localized neoplastic process with a necrotic center, but this potential is less likely than the other diagnoses in the differential list. I am expecting a favorable prognosis.

AGE

3 years

WEIGHT

19.4

HOSPITAL NAME

The City Vet Clinic, Al
Ain Central Market

REFERRING VET

Dr. Moataz Mohamed

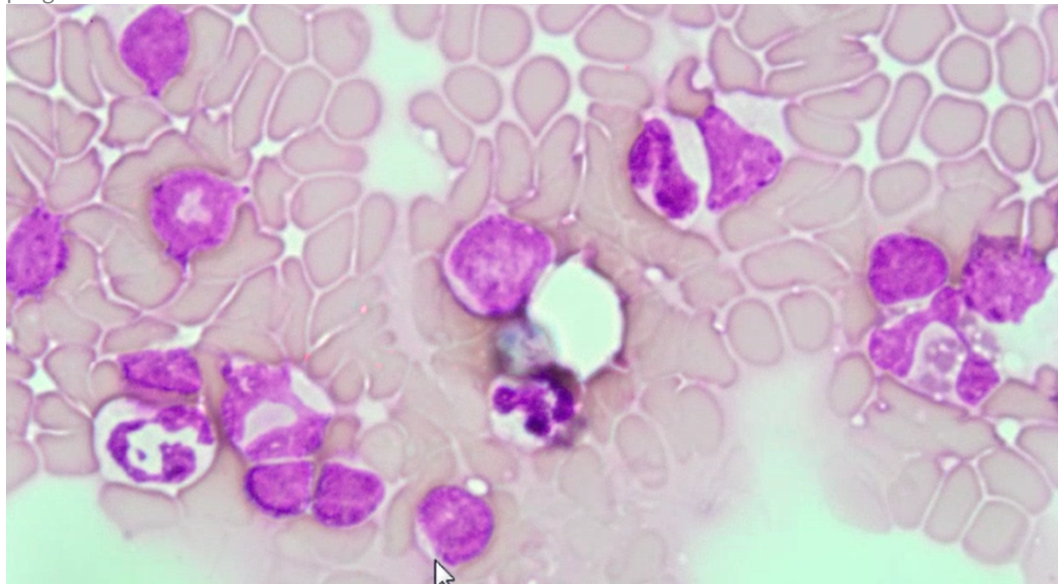


Image shows a representative cellular collection from the right flank on Asma. Neutrophils are prominent with a few mature lymphocytes and an eosinophil.

INVOICE NUMBER

40790



DATE 8/2/23 The information and recommendations provided are based on the images presented by the referring veterinarian. No evaluation can be communicated regarding pathology that was not visible in the image/video clips provided.

INTERPRETED BY L.D. McGill, DVM, Ph.D., DACVP Thank you for this referral. If the clinical or image interpretation does not parallel your findings or if I can be of any further assistance, please contact me.

L.D. McGill, DVM,
Ph.D., DACVP

L.D. McGill, DVM, Ph.D., DACVP
8288 Top of the World Drive
Cottonwood Heights, UT 84121
ldmcgill.vetpath@gmail.com
cell: 801-865-1220

PATIENT
Asma East Farm

SPECIES

Canine

BREED

saluki

SEX

Female

AGE

3 years

WEIGHT

19.4

HOSPITAL NAME

The City Vet Clinic, Al
Ain Central Market

REFERRING VET

Dr. Moataz Mohamed

INVOICE NUMBER

40790