



**DATE PRESENTING CLINICAL SIGNS**

8/17/22

One month history of vomiting and diarrhea, used to be controlled well on hypoallergenic diet, but no longer working to control symptoms  
Bloodwork - NSF, UA - USG 1.019 - no other concerns; Ultrasound - thickening of small bowel noted and mesenteric lymph nodes all enlarged - obtained FNAs from mesenteric lymph nodes

**INTERPRETED BY**

L.D. McGill, DVM,  
Ph.D, DACVP

**CYTOLOGY SUBMISSION**

Mesenteric lymph node

**OBSERVATIONS**

Mesenteric lymph node: Submitted are 9 excellent videos of excellent collections of cells from the mesenteric lymph node in Gustav. The cellularity consists of large numbers of small mature lymphocytes interspersed with reactive lymphoid cells or intermediate lymphoid cells and scattered larger lymphoid cells. Neutrophils and eosinophils are scattered throughout. Macrophages are rare. The majority of the lymphocytes (60 to 70%) are small mature lymphocytes.

**SPECIES**

Feline

**INTERPRETATION OF THE FINDINGS & FURTHER RECOMMENDATIONS**

Mesenteric lymph node - Chronic suppurative lymphadenitis with reactive or stimulated lymphoid tissue. (Please see comments)

**COMMENTS**

**BREED**

DSH

The cellularity in this collection supports inflammation and antigenic change draining to this lymph node. This could be due to inflammation in the intestine or could be due to damage to the intestine from intestinal lymphoma. Intestinal lymphoma commonly does not affect the mesenteric lymph nodes. The cells that cause intestinal lymphoma have markers that only allow them to grow in the intestine. Therefore they do not affect the regional lymph nodes. Biopsies or aspirates of the intestinal wall in Gustav is encouraged. These lymph nodes could be reacting to secondary inflammation caused by lymphoma in the intestinal wall or they could be secondary to inflammation in the intestine. Generally when there is suppurative inflammation in the intestine, the neutrophilic response is even more severe than observed in these videos and thus I am most concerned about the possibility of intestinal lymphoma. An unfavorable prognosis is warranted due to my suspicion of intestinal lymphoma which is not reflected in these lymph node aspirates.

**SEX**

Male Neutered

**AGE**

17y

**WEIGHT**

9.5#

**HOSPITAL NAME**

Ruidoso Animal Clinic

**REFERRING VET**

Dr. Favis

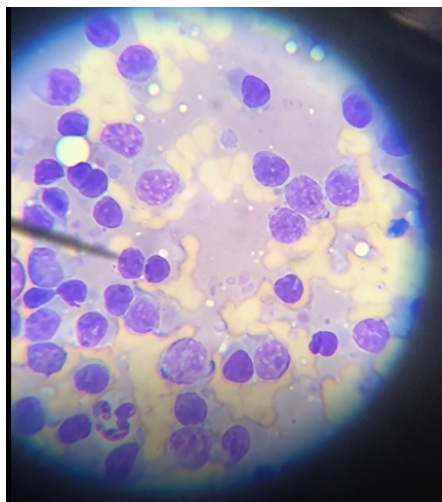


Image shows a representative collection of cells from the mesenteric lymph node in Gustav. Most of the lymphocytes are small and mature. There are reactive lymphocytes and a neutrophil.

**INVOICE NUMBER**

777



**DATE** 8/17/22 The information and recommendations provided are based on the images presented by the referring veterinarian. No evaluation can be communicated regarding pathology that was not visible in the image/video clips provided.

**INTERPRETED BY** L.D. McGill, DVM, Ph.D., DACVP Thank you for this referral. If the clinical or image interpretation does not parallel your findings or if I can be of any further assistance please contact me.

L.D. McGill, DVM,  
Ph.D., DACVP

**L.D. McGill, DVM, Ph.D., DACVP**  
8288 Top of the World Drive  
Cottonwood Heights, UT 84121  
ldmcgill.vetpath@gmail.com  
cell: 801-865-1220

**PATIENT**

Gustav Ramirez

**SPECIES**

Feline

**BREED**

DSH

**SEX**

Male Neutered

**AGE**

17y

**WEIGHT**

9.5#

**HOSPITAL NAME**

Ruidoso Animal Clinic

**REFERRING VET**

Dr. Favis

**INVOICE NUMBER**

777