



DATE PRESENTING CLINICAL SIGNS

8/17/22

Weight loss, decreased appetite, ~100+ mls of straw colored pleural effusion removed and sent to the hospital's lab. Enlarged MILN noted on AUS. FNA of MILN submitted through SonoPath. Hct 23.9, Neuts 10.48, Glu 187, SDMA 19, Glob 5.7, Bun 9, Creat 0.7

INTERPRETED BY CYTOLOGY SUBMISSION

L.D. McGill, DVM,
Ph.D, DACVP

Mesenteric lymph node

OBSERVATIONS

Mesenteric lymph node: Submitted are 4 excellent videos of excellent collections of cells from the mesenteric lymph node in Fergie. The cellularity is mixed with very few lymphocytes. The majority of the cells are neutrophils interspersed with scattered macrophages with a foamy vacuolated to granulated cytoplasm. There are very few spindle cells in one or two fields. The macrophages are reactive. Neutrophils are non-degenerate and thus sepsis is not suggested. There is no suggestion of malignancy.

PATIENT

Fergie Nance

SPECIES INTERPRETATION OF THE FINDINGS & FURTHER RECOMMENDATIONS

Feline

Mesenteric lymph node - Pyogranulomatous lymphadenitis (please see comments)

COMMENTS

The most common cause of pyogranulomatous inflammation in the lymph node in the cat is FIP. The cellular changes strongly support that diagnosis. There is no suggestion of neoplasia. Evaluation for feline coronavirus in Fergie is in order. Some laboratories may be able to do PCR on these smears. An unfavorable prognosis is warranted in my opinion. Certainly you can attempt therapy and there are some new therapies for FIP but again the prognosis is only good if Fergie responds positively towards that therapy.

BREED

DSH

SEX

Female Spayed

AGE

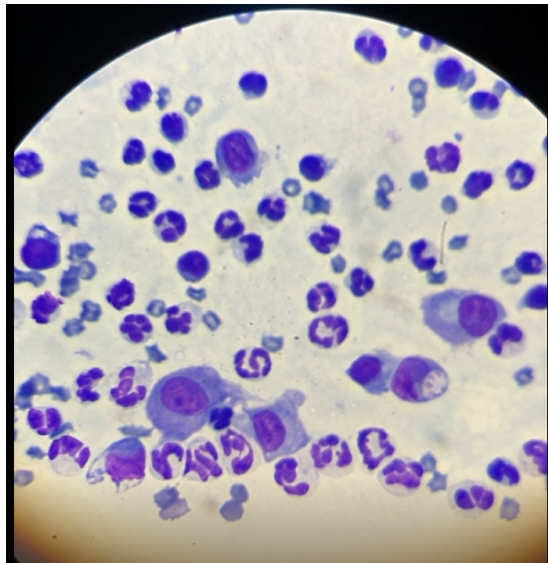
1.5yrs

WEIGHT

8.7#

HOSPITAL NAME

Tranquility Veterinary
Clinic



REFERRING VET

Dr. House

Image shows a representative collection of cells from the mesenteric lymph node in Fergie. The major cellularity consists of neutrophils. The larger cells are macrophages.

INVOICE NUMBER

776



DATE 8/17/22 The information and recommendations provided are based on the images presented by the referring veterinarian. No evaluation can be communicated regarding pathology that was not visible in the image/video clips provided.

INTERPRETED BY L.D. McGill, DVM, Ph.D., DACVP Thank you for this referral. If the clinical or image interpretation does not parallel your findings or if I can be of any further assistance please contact me.

L.D. McGill, DVM,
Ph.D., DACVP

L.D. McGill, DVM, Ph.D., DACVP
8288 Top of the World Drive
Cottonwood Heights, UT 84121
ldmcgill.vetpath@gmail.com
cell: 801-865-1220

PATIENT

Fergie Nance

SPECIES

Feline

BREED

DSH

SEX

Female Spayed

AGE

1.5yrs

WEIGHT

8.7#

HOSPITAL NAME

Tranquility Veterinary
Clinic

REFERRING VET

Dr. House

INVOICE NUMBER

776