



DATE PRESENTING CLINICAL SIGNS

8/16/22

Patient presented for abd. U/S on 8/4/23. An irregular heteroechoic mass was found near trigon of the bladder. Mass is 1.6 cm x 0.8 cm. Traumatic urinary catheterization was performed 8/17/23 to obtain cells for pathology review.

INTERPRETED BY CYTOLOGY SUBMISSION

Urinary collection

L.D. McGill, DVM,
Ph.D, DACVP

OBSERVATIONS

Urinary tract: Submitted are 4 excellent videos of cells collected from the urinary tract in Marley. The cellularity consists of large packets of epithelial cells. The epithelial cells are aggregated and irregular with slight anisocytosis and slight anisokaryosis. There is minimal inflammation.

PATIENT

Marley Montone

INTERPRETATION OF THE FINDINGS & FURTHER RECOMMENDATIONS

Urinary tract - Suggestive of urothelial carcinoma, low-grade.

SPECIES COMMENTS

Feline

The cellularity supports a proliferative process of epithelium. The epithelial cells demonstrate anisokaryosis and anisocytosis. This suggests neoplasia but is not classical. There is minimal inflammation in this collected material. The epithelial cells are suggestive but not diagnostic of a neoplastic process. Surgical biopsy may be required to confirm the process in this region. A guarded prognosis is certainly warranted.

BREED

DSH

SEX

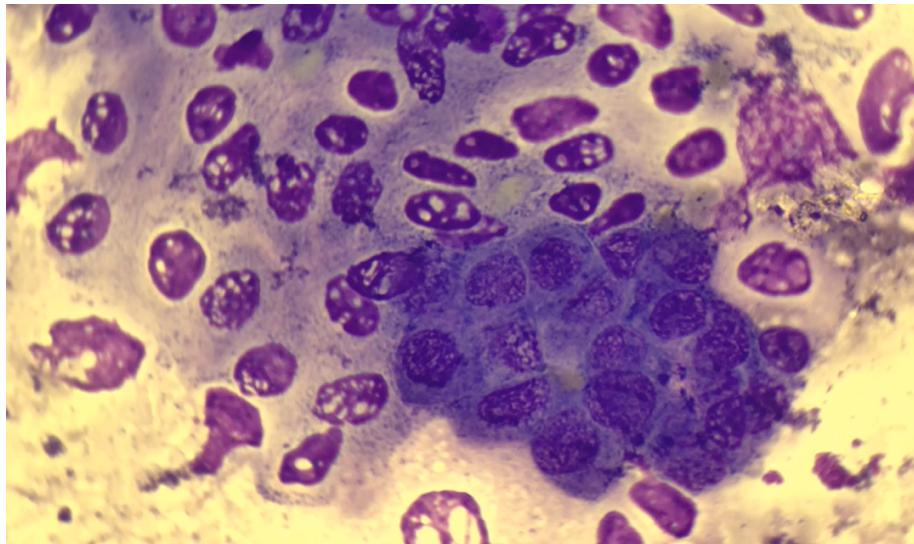
Male Neutered

AGE

16y

WEIGHT

18.1 lbs



HOSPITAL NAME

Rotterdam Veterinary
Hospital

Image shows a group of irregular epithelial cells collected from the urinary tract in Marley. Note the anisocytosis and anisokaryosis.

The information and recommendations provided are based on the images presented by the referring veterinarian. No evaluation can be communicated regarding pathology that was not visible in the image/video clips provided.

REFERRING VET

Dr. St. Sir

Thank you for this referral. If the clinical or image interpretation does not parallel your findings or if I can be of any further assistance please contact me.

INVOICE NUMBER

988



DATE L.D. McGill, DVM, Ph.D., DACVP

8/16/22
8288 Top of the World Drive
Cottonwood Heights, UT 84121
ldmcgill.vetpath@gmail.com
cell: 801-865-1220

INTERPRETED BY

L.D. McGill, DVM,
Ph.D., DACVP

PATIENT

Marley Montone

SPECIES

Feline

BREED

DSH

SEX

Male Neutered

AGE

16y

WEIGHT

18.1 lbs

HOSPITAL NAME

Rotterdam Veterinary
Hospital

REFERRING VET

Dr. St. Sir

INVOICE NUMBER

988