



DATE PRESENTING CLINICAL SIGNS

8/16/22

Ambulatory x 3. Non weight bearing on R forelimb. Firm and painful swelling at R shoulder. FNA prior to appointment with specialist

INTERPRETED BY

CYTOLOGY SUBMISSION

Right forelimb mass

L.D. McGill, DVM,
Ph.D, DACVP

OBSERVATIONS

Right forelimb mass: Submitted are 7 excellent videos of moderate to excellent collections of cells from the mass on the forelimb on Tiaga. The cellularity consists of a proliferation of rounded cells growing irregularly. Many of the cells are individualized and in some areas they are localized. Mitotic figures are identified. There is prominent anisocytosis and anisokaryosis. Some cells are degenerate. There are a few inflammatory cells scattered in some of the fields but they are not the most numerous cells. Red blood cells are present in the background.

PATIENT

Tiaga Fireside

INTERPRETATION OF THE FINDINGS & FURTHER RECOMMENDATIONS

SPECIES

Right forelimb mass - Round cells sarcoma suggestive of a histiocytic sarcoma or possible osteosarcoma.

Canine

COMMENTS

BREED

Malamute

This is definitely a round cell sarcoma. The majority of the cellularity suggests a histiocytic sarcoma. There are even some areas that suggest the possibility of lymphoma but that is not the most likely from the cells. Due to problems in the bone, I am concerned about the potential of an osteosarcoma or even a synovial sarcoma which is histiocytic in nature. This mass is so large, that wide excision will probably require amputation. An unfavorable prognosis is due to the cellularity and the problems in the bone itself. Continued evaluation to determine the extent of the proliferative process is encouraged. Evaluation for internal metastasis is encouraged.

SEX

Male Neutered

AGE

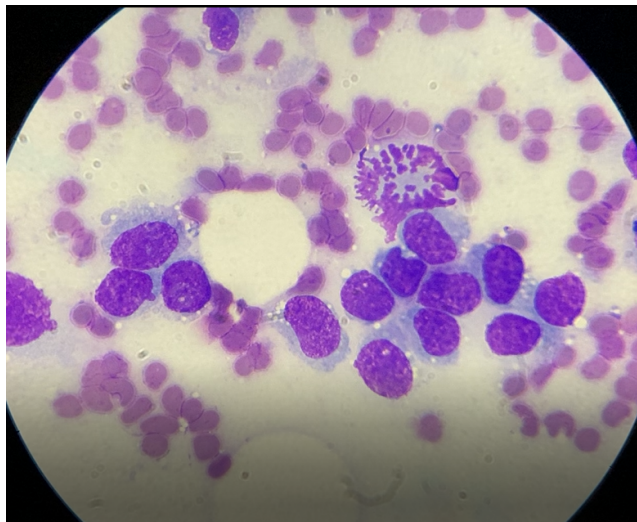
8y

WEIGHT

131 lbs

HOSPITAL NAME

The Ark Veterinary
Clinic



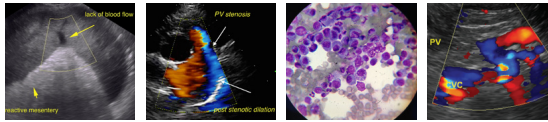
REFERRING VET

Dr. Sangl

Image shows a group of neoplastic round cells with a mitotic figure collected from the foreleg lesion on Tiaga. Note the anisokaryosis in the round cells.

INVOICE NUMBER

774



DATE 8/16/22 The information and recommendations provided are based on the images presented by the referring veterinarian. No evaluation can be communicated regarding pathology that was not visible in the image/video clips provided.

INTERPRETED BY L.D. McGill, DVM, Ph.D., DACVP Thank you for this referral. If the clinical or image interpretation does not parallel your findings or if I can be of any further assistance please contact me.

L.D. McGill, DVM,
Ph.D., DACVP

L.D. McGill, DVM, Ph.D., DACVP
8288 Top of the World Drive
Cottonwood Heights, UT 84121
ldmcgill.vetpath@gmail.com
cell: 801-865-1220

PATIENT
Tiaga Fireside

SPECIES

Canine

BREED

Malamute

SEX

Male Neutered

AGE

8y

WEIGHT

131 lbs

HOSPITAL NAME

The Ark Veterinary
Clinic

REFERRING VET

Dr. Sangl

INVOICE NUMBER

774