



**DATE PRESENTING CLINICAL SIGNS**

8/13/21

History of chronic diarrhea, now with vomiting and weight loss.

**INTERPRETED BY CYTOLOGY SUBMISSION**

L.D. McGill, DVM,  
Ph.D., DACVP

FNA of Liver.

PE: BCS 3/9 with muscle wasting, but BAR. SI feel subjectively thickened and ropey.

AUS: mildly to moderately enlarged mesenteric LN. Rounded edges to liver, mildly big.

**PATIENT OBSERVATIONS**

Gem Johnson

Liver: Submitted are several videos collected from the cells from the liver in Gem. There are few hepatocytes. The hepatocytes show vacuoles and slight granularity. The surrounding RBCs include a few neutrophils and scattered lymphocytes. There is no suggestion of neoplasia. The inflammation is minimal.

**SPECIES**

Feline

**INTERPRETATION OF THE FINDINGS & FURTHER RECOMMENDATIONS**

Liver - Early vacuolization and possible early lipidosis with mild inflammation.

**BREED**

DLH

**COMMENTS**

There are minimal numbers of hepatocytes to evaluate. This may be early lipidosis or there could be fibrosis. If problems continue, then a follow up biopsy may be necessary. There is no suggestion of neoplasia. The inflammation is minimal and non specific. When I see these changes I always wonder about pancreatitis. The changes are not specific.

**SEX**

Male Neutered

**AGE**

4 years

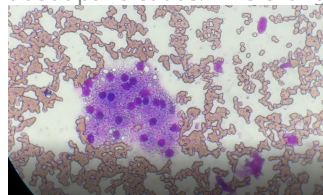


Image shows hepatocytes with vacuoles and granularity. There are a few inflammatory cells in the surrounding RBCs. Not much to make a diagnosis on??

**WEIGHT**

7.9 lbs

**The information and recommendations provided are based on the images presented by the referring veterinarian. No evaluation can be communicated regarding pathology that was not visible in the image/video clips provided.**

**HOSPITAL NAME**

Scanvet

Thank you for this referral. If the clinical or image interpretation does not parallel your findings or if I can be of any further assistance please contact me.

**REFERRING VET**

Dr. Mirecki

**L.D. McGill, DVM, Ph.D., DACVP**

8288 Top of the World Drive  
Cottonwood Heights, UT 84121  
ldmcgill.vetpath@gmail.com  
cell: 801-865-1220

**INVOICE NUMBER**

70395



**DATE**

8/13/21

**INTERPRETED BY**

L.D. McGill, DVM,  
Ph.D., DACVP

**PATIENT**

Gem Johnson

**SPECIES**

Feline

**BREED**

DLH

**SEX**

Male Neutered

**AGE**

4 years

**WEIGHT**

7.9 lbs

**HOSPITAL NAME**

Scanvet

**REFERRING VET**

Dr. Mirecki

**INVOICE NUMBER**

70395