



DATE PRESENTING CLINICAL SIGNS

8/12/22

Vascular Intestinal mass with ill-defined margins; reactive regional mesenteric lymph nodes.

INTERPRETED BY CYTOLOGY SUBMISSION

FNA of intestinal mass

L.D. McGill, DVM,
Ph.D, DACVP

OBSERVATIONS

Intestinal mass: Submitted are 4 excellent videos of excellent collections of cells from the intestinal mass in Mittens. The cellularity in most of the fields consists of round cells. These cells are lymphoid cells with irregular cytoplasm that is bluish gray. The nuclei are rounded and euchromatic. There is some smudged nuclear material throughout the cellularity suggesting degeneration. Scattered neutrophils and rare eosinophils are present with rare macrophages. The majority of the cells are small to intermediate sized lymphocytes.

PATIENT

Mittens Tierno

SPECIES

Feline

INTERPRETATION OF THE FINDINGS & FURTHER RECOMMENDATIONS

Intestinal mass - Small to intermediate cell lymphoma with mild inflammation.

BREED

DSH

COMMENTS

The cellularity in this collection is characteristic of lymphoma. There is some mild inflammation and degeneration. The lymphoid cells suggest a small to intermediate cell lymphoma. If this mass is localized, excision of the mass may be beneficial in extending the life in Mittens. Immunophenotyping the cells can be of benefit in treatment. Prognosis may not be confirmed with immunophenotyping. An unfavorable prognosis is warranted in the long run with this type of cellular collection from the intestine.

SEX

FS

AGE

11 years

WEIGHT

5#

HOSPITAL NAME

Animal Care Centers of
Landing

REFERRING VET

Dr. Casulli

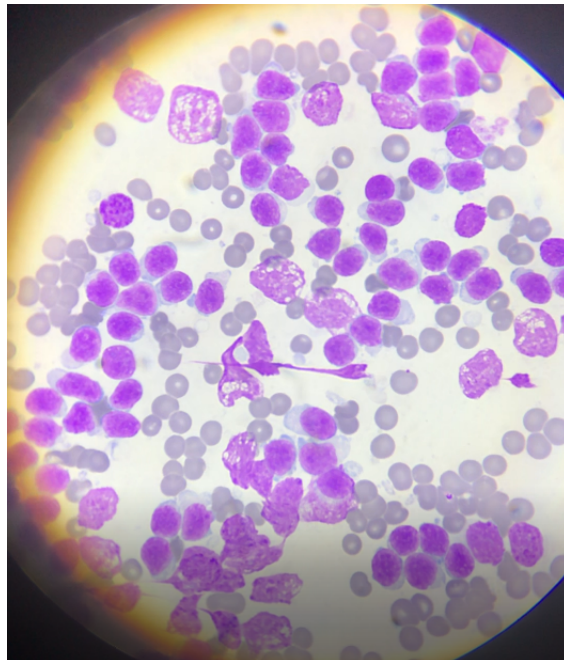


Image shows a representative group of cells collected from the intestinal mass in Mittens. There are some degenerate nuclei. This cellularity is consistent with most fields in this collection. Some fields contain neutrophils and rare eosinophils.

INVOICE NUMBER

40580



DATE

8/12/22

The information and recommendations provided are based on the images presented by the referring veterinarian. No evaluation can be communicated regarding pathology that was not visible in the image/video clips provided.

INTERPRETED BY

L.D. McGill, DVM,
Ph.D, DACVP

Thank you for this referral. If the clinical or image interpretation does not parallel your findings or if I can be of any further assistance, please contact me.

PATIENT

Mittens Tierno

L.D. McGill, DVM, Ph.D., DACVP
8288 Top of the World Drive
Cottonwood Heights, UT 84121
ldmcgill.vetpath@gmail.com
cell: 801-865-1220

SPECIES

Feline

BREED

DSH

SEX

FS

AGE

11 years

WEIGHT

5#

HOSPITAL NAME

Animal Care Centers of
Landing

REFERRING VET

Dr. Casulli

INVOICE NUMBER

40580