



DATE PRESENTING CLINICAL SIGNS

8/11/17
Inappetence, vomiting and weight loss. Apx. 1 month history of off and on eating.
BW (7-21-21): BUN 5, Alb 2.1, Glob 4.8. Chol 346 H. WBC 31,140 w/86% Neut., 6% Monos.
AUS: focal peritonitis around a cystic lesion and inflammation around the ICJ.
Several disruptive, expansive splenic lesions.

INTERPRETED BY

L.D. McGill, DVM,
Ph.D., DACVP

CYTOLOGY SUBMISSION

FNA of Spleen.

OBSERVATIONS

PATIENT Spleen: Submitted are 11 videos of excellent collections of cells from the spleen in Harley. The cellularity consists of large numbers of neutrophils of varying stages with scattered lymphocytes and nucleated RBCs. The neutrophils are overwhelming in numbers throughout all of the smears. Bacteria were not noted. These neutrophils are adequate in numbers to assist in making a diagnosis.

Harley Lecompte

SPECIES

Canine

INTERPRETATION OF THE FINDINGS & FURTHER RECOMMENDATIONS

Spleen -Severe chronic suppurative splenitis with no evidence of malignancy.

COMMENTS

BREED

Pug

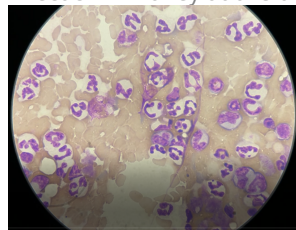
The changes in the smears are characteristic of a suppurative inflammatory response in the spleen. There is no suggestion of neoplasia. This suppurative response could easily be due to infection in any location in the abdominal cavity or it could be due to a septic process. I did not identify any bacteria in this collection from Harley. Antibiotic therapy is encouraged and it may require prolonged treatment. It would also be a good idea to evaluate for a potential source for inflammation including enteritis or pancreatitis. A guarded prognosis is warranted due to the potential of a rather severe infection in Harley at this time.

SEX

FS

AGE

12 years



WEIGHT

15.6 blbs

Image shows a representative field in the smears collected from the spleen in Harley. Note the large numbers of neutrophils.

The information and recommendations provided are based on the images presented by the referring veterinarian. No evaluation can be communicated regarding pathology that was not visible in the image/video clips provided.

HOSPITAL NAME

Scanvet

Thank you for this referral. If the clinical or image interpretation does not parallel your findings or if I can be of any further assistance please contact me.

REFERRING VET

Dr Sanders

L.D. McGill, DVM, Ph.D., DACVP

8288 Top of the World Drive
Cottonwood Heights, UT 84121
ldmcgill.vetpath@gmail.com
cell: 801-865-1220

INVOICE NUMBER

70397



DATE

8/11/17

INTERPRETED BY

L.D. McGill, DVM,
Ph.D, DACVP

PATIENT

Harley Lecompte

SPECIES

Canine

BREED

Pug

SEX

FS

AGE

12 years

WEIGHT

15.6 blbs

HOSPITAL NAME

Scanvet

REFERRING VET

Dr Sanders

INVOICE NUMBER

70397