



DATE PRESENTING CLINICAL SIGNS

8/11/23

Not doing well, anorexic

INTERPRETED BY CYTOLOGY SUBMISSION

L.D. McGill, DVM,
Ph.D, DACVP

FNA of Prostate

PATIENT OBSERVATIONS

Buddy Terry

Prostate: Submitted are 7 excellent videos of excellent collections of cells from the prosthetic region in Buddy. The cellularity consists of large numbers of epithelial cells mainly in packets with moderate to marked anisokaryosis and anisocytosis. There are very few inflammatory cells but neutrophils can be identified. Rod shaped bacteria are identified in some locations. The epithelial cells are uroepithelial cells with scattered mitotic figures. The inflammation appears to be secondary.

SPECIES

Canine

INTERPRETATION OF THE FINDINGS & FURTHER RECOMMENDATIONS

Prostate - Urothelial carcinoma with secondary inflammation.

BREED

pekeapoo

COMMENTS

SEX

Male

The cellularity in this collection is characteristic urothelial epithelial cells with vacuolization and marked anisokaryosis. There are many characteristics that support neoplasia. Inflammation is minimal but secondary. Consultation with an oncologist may be beneficial in treating Buddy. A guarded to unfavorable prognosis is warranted in my opinion. These tumors are difficult to treat. This type of growth is the most common tumor in the prostate in the dog. These are different tumors than identified in man.

AGE

13y

WEIGHT

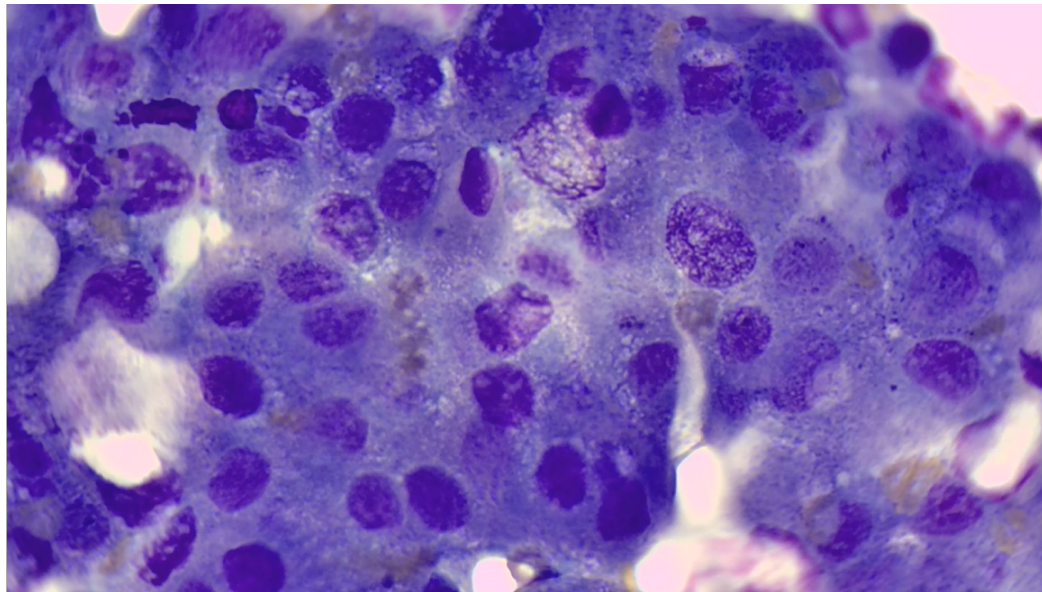
8.8lbs

HOSPITAL NAME

Rotterdam Veterinary
Hospital

REFERRING VET

Dr. Anna St.Sir



INVOICE NUMBER

40798

The image shows a group of epithelial cells collected from the prostate in Buddy. There are one or two mitotic figures in this field. Note the anisokaryosis is quite prominent.



DATE

8/11/23 The information and recommendations provided are based on the images presented by the referring veterinarian. No evaluation can be communicated regarding pathology that was not visible in the image/video clips provided.

INTERPRETED BY

L.D. McGill, DVM,
Ph.D, DACVP

Thank you for this referral. If the clinical or image interpretation does not parallel your findings or if I can be of any further assistance, please contact me.

PATIENT

L.D. McGill, DVM, Ph.D., DACVP
8288 Top of the World Drive
Cottonwood Heights, UT 84121
ldmcgill.vetpath@gmail.com
cell: 801-865-1220

SPECIES

Canine

BREED

pekeapoo

SEX

Male

AGE

13y

WEIGHT

8.8lbs

HOSPITAL NAME

Rotterdam Veterinary
Hospital

REFERRING VET

Dr. Anna St.Sir

INVOICE NUMBER

40798