



**DATE PRESENTING CLINICAL SIGNS**

8/11/21

Mass in throat region; FNA performed on mass, appears to be left thyroid

**CYTOLOGY SUBMISSION**

FNA of Thyroid region

**INTERPRETED BY**

L.D. McGill, DVM,  
Ph.D., DACVP

**OBSERVATIONS**

Thyroid region: Submitted are 7 excellent videos of moderate to excellent collections of cells from the thyroid region in Shea. In the first 2 videos, there are large numbers of inflammatory cells including neutrophils and macrophages. The macrophages have a foamy cytoplasm. There were no characteristics of neoplasia in those videos. In the other videos, there are large aggregates of cells that are packeted in irregular patterns. They have bluish gray cytoplasm. There is anisocytosis and anisokaryosis in these cells. They are prominent throughout the last five videos. Many of the cells have rounded nuclei.

**PATIENT**

Shea Bridges

**SPECIES INTERPRETATION OF THE FINDINGS & FURTHER RECOMMENDATIONS**

Canine

Thyroid region - Pyogranulomatous inflammation with packets of cells consistent with thyroid carcinoma.

**COMMENTS**

**BREED**

Boxer

The cellularity in the proliferative part of these videos suggests an epithelial proliferation or neuroendocrine proliferation of cells. These cells have more cytoplasm than I usually attribute to thyroid carcinoma cells but with the irregular nuclei, thyroid carcinoma has to be considered. There are scattered packets of eosinophilic material that could be thyroglobulin. This cellularity is definitely irregular and there are adequate numbers of packets of cells to suggest a neoplastic process. Excision of this mass is encouraged even though this may be an extremely bloody surgery.

**SEX**

Male Neutered

**AGE**

12 year

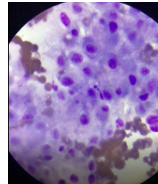


Image shows a group of cells collected from the thyroid area on Shea. Note the anisokaryosis.

**WEIGHT**

78#

**The information and recommendations provided are based on the images presented by the referring veterinarian. No evaluation can be communicated regarding pathology that was not visible in the image/video clips provided.**

**HOSPITAL NAME**

Butler Veterinary  
Hospital

Thank you for this referral. If the clinical or image interpretation does not parallel your findings or if I can be of any further assistance please contact me.

**L.D. McGill, DVM, Ph.D., DACVP**

8288 Top of the World Drive  
Cottonwood Heights, UT 84121

**REFERRING VET**

Dr. Garro

ldmcgill.vetpath@gmail.com

cell: 801-865-1220

**INVOICE NUMBER**

70393



**DATE**

8/11/21

**INTERPRETED BY**

L.D. McGill, DVM,  
Ph.D., DACVP

**PATIENT**

Shea Bridges

**SPECIES**

Canine

**BREED**

Boxer

**SEX**

Male Neutered

**AGE**

12 year

**WEIGHT**

78#

**HOSPITAL NAME**

Butler Veterinary  
Hospital

**REFERRING VET**

Dr. Garro

**INVOICE NUMBER**

70393