



**DATE PRESENTING CLINICAL SIGNS**

8/10/23 Enlarged submand

**INTERPRETED BY CYTOLOGY SUBMISSION**

L.D. McGill, DVM,  
Ph.D, DACVP

Submandibular lymph node: Submitted are 2 excellent videos of excellent collections of cells from the submandibular lymph node in Annabelle. The cellularity is mixed. There are prominent small mature lymphocytes with scattered reactive lymphoid cells and large numbers of plasma cells. Scattered neutrophils and rare eosinophils are identified. There are occasional macrophages in the videos. Malignant characteristics are not identified.

**PATIENT**

Annabelle Beauchaine

**OBSERVATIONS**

Submandibular lymph node: Submitted are 2 excellent videos of excellent collections of cells from the submandibular lymph node in Annabelle. The cellularity is mixed. There are prominent small mature lymphocytes with scattered reactive lymphoid cells and large numbers of plasma cells. Scattered neutrophils and rare eosinophils are identified. There are occasional macrophages in the videos. Malignant characteristics are not identified.

**SPECIES**

Canine

**BREED**

Lhasa

**INTERPRETATION OF THE FINDINGS & FURTHER RECOMMENDATIONS**

Submandibular lymph node - Markedly reactive lymph node with evidence of antigenic stimulus and inflammation.

**SEX**

FS

**AGE**

11

**COMMENTS**

The cellularity is characteristic of a reactive lymph node with marked plasma cell response. The plasma cell response supports an antigenic reaction with the likelihood of antibody formation against some type of stimulus. This could be bacteria or viral or even a foreign body. This is an inflamed lymph node with reactive lymphoid tissue and an antigenic response. This inflammatory process could be anywhere over the head or neck region. Treatment for inflammation and antibiotic therapy is encouraged. There is no suggestion of neoplasia. A guarded prognosis is warranted since the underlying process is not identified.

**WEIGHT**

15

**HOSPITAL NAME**

Bayshore Veterinary  
Hospital

**REFERRING VET**

Dr. Hunt

**INVOICE NUMBER**

40797



**DATE**

8/10/23

**INTERPRETED BY**

L.D. McGill, DVM,  
Ph.D, DACVP

**PATIENT**

Annabelle Beauchaine

**SPECIES**

Canine

**BREED**

Lhasa

**SEX**

FS

**AGE**

11

**WEIGHT**

15

**HOSPITAL NAME**

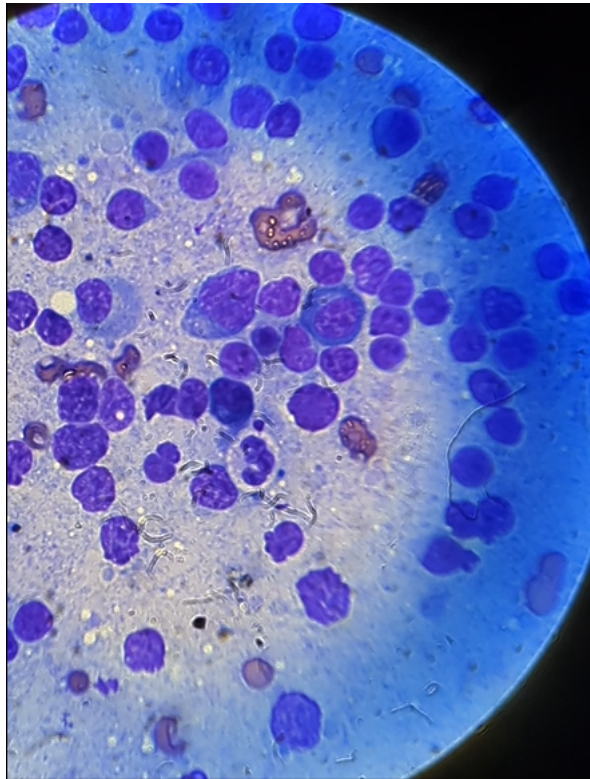
Bayshore Veterinary  
Hospital

**REFERRING VET**

Dr. Hunt

**INVOICE NUMBER**

40797



The image shows a good group of cells collected from the submandibular lymph node in Annabelle. There are plasma cells in the collection and a neutrophil with many small reactive lymphoid cells.

The information and recommendations provided are based on the images presented by the referring veterinarian. No evaluation can be communicated regarding pathology that was not visible in the image/video clips provided.

Thank you for this referral. If the clinical or image interpretation does not parallel your findings or if I can be of any further assistance, please contact me.

L.D. McGill, DVM, Ph.D., DACVP  
8288 Top of the World Drive  
Cottonwood Heights, UT 84121  
ldmcgill.vetpath@gmail.com  
cell: 801-865-1220