



DATE PRESENTING CLINICAL SIGNS

8/10/21

decreased appetite, vomiting. US showed intestinal mass. FNA of mass performed

CYTOLOGY SUBMISSION

Intestinal Mass

INTERPRETED BY

L.D. McGill, DVM,
Ph.D., DACVP

OBSERVATIONS

Intestinal Mass: Submitted are 9 excellent videos of moderate collections of cells from the intestinal mass in Jimmy. There is a mixture of cells which include neutrophils, a few lymphocytes and moderate numbers of macrophages. The macrophages have foamy vacuolated cytoplasm and prominent cytoplasm. The neutrophils range from non-degenerate to slightly degenerate. I did not identify any bacteria. There are no characteristics of malignancy in these cells.

PATIENT

Jimmy Galione

INTERPRETATION OF THE FINDINGS & FURTHER RECOMMENDATIONS

Intestinal Mass - Pyogranulomatous inflammation

SPECIES

feline

COMMENTS

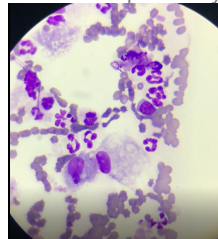
The cellularity is characteristic of a chronic inflammatory process. This is pyogranulomatous in nature. The most common cause in older cats is feline infectious peritonitis. Intestinal trauma and penetrating lesions might cause this type of response. There is no suggestion of malignancy, and I cannot confirm sepsis. Bacterial infection may be a part of the process. PCR testing of these slides may be beneficial in confirming coronavirus infection in Jimmy. A guarded to unfavorable prognosis is warranted with this observation. There have been some experimental therapies that are positive with FIP. Exploratory and excision of the mass may prolong life in Jimmy.

BREED

DSH

SEX

Male Neutered



AGE

9 years

Image shows 2 large macrophages associated with neutrophils and a lymphocyte in the good collection from the intestinal mass in Jimmy. Bacteria are not observed.

WEIGHT

6.6#

The information and recommendations provided are based on the images presented by the referring veterinarian. No evaluation can be communicated regarding pathology that was not visible in the image/video clips provided.

HOSPITAL NAME

Newton Veterinary
Hospital

Thank you for this referral. If the clinical or image interpretation does not parallel your findings or if I can be of any further assistance, please contact me.

L.D. McGill, DVM, Ph.D., DACVP

8288 Top of the World Drive
Cottonwood Heights, UT 84121

REFERRING VET

ldmcgill.vetpath@gmail.com
cell: 801-865-1220

N/A

INVOICE NUMBER

70392



DATE

8/10/21

INTERPRETED BY

L.D. McGill, DVM,
Ph.D, DACVP

PATIENT

Jimmy Galione

SPECIES

feline

BREED

DSH

SEX

Male Neutered

AGE

9 years

WEIGHT

6.6#

HOSPITAL NAME

Newton Veterinary
Hospital

REFERRING VET

N/A

INVOICE NUMBER

70392