



DATE PRESENTING CLINICAL SIGNS

8/1/23

Recent weight loss, decrease appetite and dental disease. Recent bloodwork shows increased Glob, and decreased ALB. On ultrasound findings, enlarged hypoechoic mesenteric lymph node, thick intestinal walls and possible 2 mm intestinal mass (large amount of stool presents).

INTERPRETED BY

L.D. McGill, DVM,
Ph.D, DACVP

CYTOLOGY SUBMISSION
Ultrasound Guided

OBSERVATIONS

PATIENT

Zorro Metz

Lymph node: Submitted are 5 excellent videos of moderate cellular collections from the lymph node in Zorro. The cellularity consists of large numbers of lymphoid cells, the majority of which are small mature lymphocytes. There are scattered irregular cells that appear to be enlarged but these are few in numbers. There are scattered macrophages and there are scattered neutrophils throughout the collection. Some reactive lymphoid cells are identified. There are aggregates of platelets in a few fields. There is a slight hemodiluted background.

SPECIES

Feline

BREED

DSH

INTERPRETATION OF THE FINDINGS & FURTHER RECOMMENDATIONS

Lymph node - Large numbers of small mature lymphocytes consistent with reactive or stimulated lymph node with mild pyogranulomatous inflammation.

SEX

Male Neutered

COMMENTS

The cellularity in this collection supports a reactive lymph node and mild inflammation. This node may not reflect what is occurring within the intestine. Intestinal lymphoma may involve lymphoid cells that are carrying histiocytic markers that only allow them to grow in the intestine. Intestinal lymphoma is often not reflected in the regional lymph nodes. The regional lymph nodes respond to inflammation which is occurring secondarily to the lymphoma in the intestine. When there is intestinal lymphoma, aspirates of the intestinal wall or intestinal mass are encouraged since the lymph node may not be reflective of the process. There is some inflammation in the lymph node tissue collected. With the inflammation, I cannot rule out the possibility of FIP being involved in this case. A guarded to unfavorable prognosis is warranted since the underlying process is not identified in this collection from Zorro.

AGE

10yrs

WEIGHT

9.4lbs

HOSPITAL NAME

Central Veterinary
Hospital

REFERRING VET

Dr. Anna St. Sir

INVOICE NUMBER

804



DATE

8/1/23

INTERPRETED BY

L.D. McGill, DVM,
Ph.D, DACVP

PATIENT

Zorro Metz

SPECIES

Feline

BREED

DSH

SEX

Male Neutered

AGE

10yrs

WEIGHT

9.4lbs

HOSPITAL NAME

Central Veterinary
Hospital

REFERRING VET

Dr. Anna St. Sir

INVOICE NUMBER

804

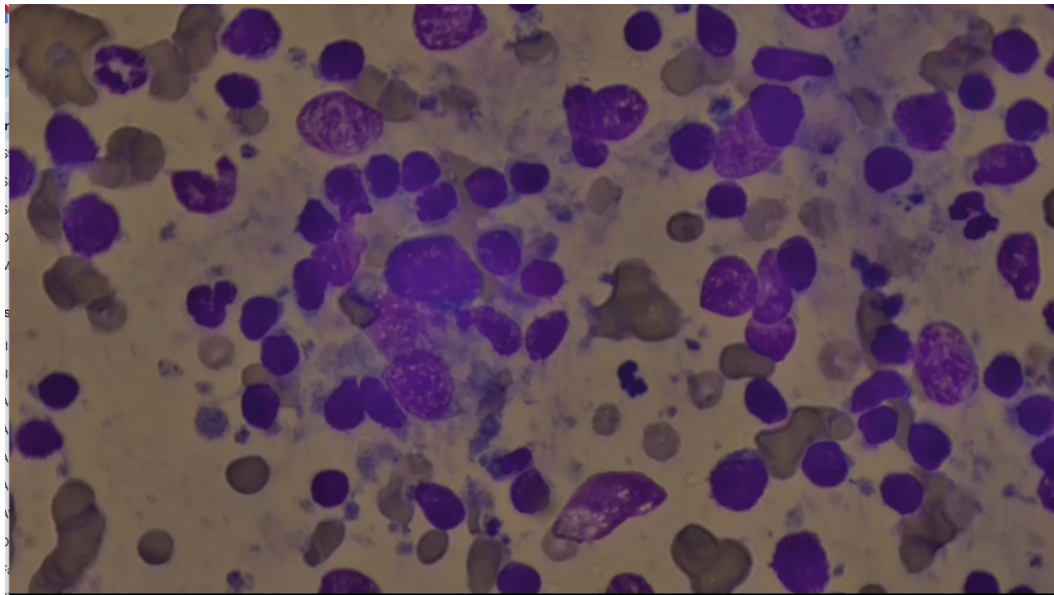


Image demonstrates large numbers of small mature lymphocytes with macrophages and scattered neutrophils collected from the lymph node in Zorro. The majority of the lymphocytes are small mature cells.

The information and recommendations provided are based on the images presented by the referring veterinarian. No evaluation can be communicated regarding pathology that was not visible in the image/video clips provided.

Thank you for this referral. If the clinical or image interpretation does not parallel your findings or if I can be of any further assistance please contact me.

L.D. McGill, DVM, Ph.D., DACVP
8288 Top of the World Drive
Cottonwood Heights, UT 84121
ldmcgill.vetpath@gmail.com
cell: 801-865-1220