



**DATE PRESENTING CLINICAL SIGNS**

7/6/22

Patient presented for problem exam 7/5/2022 for urine incontinence. Per owner, seems uncomfortable, hunched posture. Strains to urinate occasionally. Panting more frequently. Heart murmur I/VI. Abdomen painful on palpation. Ultrasound performed day of exam which showed enlarged prostate, hetero-hyperechoic tissue. Sample collected via traumatic catheterization.

**INTERPRETED BY**

L.D. McGill, DVM,  
Ph.D, DACVP

**CYTOLOGY SUBMISSION**

FNA of Urethral collection

**PATIENT**

Otis Cassels

**OBSERVATIONS**

Urethral collection: Submitted are 4 excellent videos of minimal to moderate cellular collections from the urethral region in Otis. The cellularity is irregular. There is anisocytosis and anisokaryosis in the collection. Some of the cells are smudged. The cellularity is minimal.

**SPECIES**

Canine

**INTERPRETATION OF THE FINDINGS & FURTHER RECOMMENDATIONS**

Urethral collection - Irregular epithelial cells supporting possible urethral carcinoma.

**BREED**

Beagle

**COMMENTS**

The cellularity is minimal but suggestive of urothelial cell carcinoma. More cells may suggest that potential more specifically. A guarded prognosis is warranted. This is the most common tumor in the canine prostatic region.

**SEX**

Male Neutered

**AGE**

12Y

**WEIGHT**

44.8#

**HOSPITAL NAME**

Rotterdam Veterinary  
Hospital

**REFERRING VET**

Dr. Anna St Sir

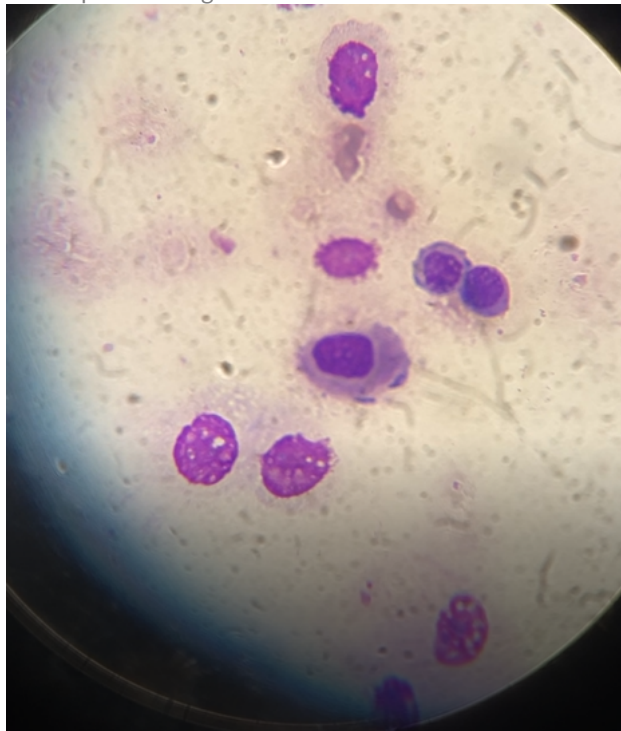


Image shows a few of the representative cells collected from the urethra in Otis. Note the anisocytosis and anisokaryosis.

**INVOICE NUMBER**

40562



**DATE**

7/6/22

The information and recommendations provided are based on the images presented by the referring veterinarian. No evaluation can be communicated regarding pathology that was not visible in the image/video clips provided.

**INTERPRETED BY**

L.D. McGill, DVM,  
Ph.D, DACVP

Thank you for this referral. If the clinical or image interpretation does not parallel your findings or if I can be of any further assistance, please contact me.

**PATIENT**

Otis Cassels

**L.D. McGill, DVM, Ph.D., DACVP**  
8288 Top of the World Drive  
Cottonwood Heights, UT 84121  
ldmcgill.vetpath@gmail.com  
cell: 801-865-1220

**SPECIES**

Canine

**BREED**

Beagle

**SEX**

Male Neutered

**AGE**

12Y

**WEIGHT**

44.8#

**HOSPITAL NAME**

Rotterdam Veterinary  
Hospital

**REFERRING VET**

Dr. Anna St Sir

**INVOICE NUMBER**

40562