



**DATE PRESENTING CLINICAL SIGNS**

7/5/22

Patient presented for anorexia, lethargy and high calcium and ionized calcium. Multiple enlarged, irregular lymph nodes were visualized from the iliac trifurcation all the way up to the gastric fundus. Concern for lymphoma vs. other.

**INTERPRETED BY CYTOLOGY SUBMISSION**

Lymph node

L.D. McGill, DVM,  
Ph.D, DACVP

**OBSERVATIONS**

Lymph node: Submitted are large numbers of images and a few videos of cells collected from the lymph node in Shea. The cellularity in general consists of large numbers of small mature lymphocytes. There are scattered reactive lymphoid cells and scattered neutrophils. The reactive lymphoid cells are enlarged. Atypical lymphoid cells are not prominent.

**PATIENT**

Shea Roufanis

**INTERPRETATION OF THE FINDINGS & FURTHER RECOMMENDATIONS**

Lymph node - Mild chronic suppurative lymphadenitis and reactive or stimulated lymph node.

**SPECIES**

Canine

**COMMENTS**

The cellularity supports chronic inflammation draining to the lymph node. The inflammation could be from any location in the abdominal cavity. There could be lymphoma in the intestine but not be represented in the lymph node. The inflammation could also be secondary to whatever is occurring in the intestine. Continued evaluation of other organs including the intestine is encouraged. This may require intestinal biopsies. A guarded prognosis is warranted due to the fact that we do not know the underlying cause of problems in Shea.

**BREED**

Labradoodle

**SEX**

Male Neutered

**AGE**

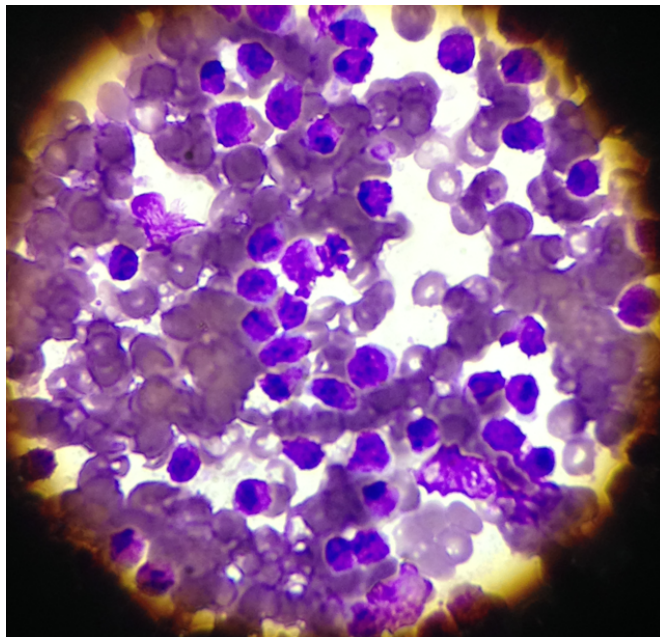
10y

**WEIGHT**

27 lbs

**HOSPITAL NAME**

New Bridge Veterinary  
Practice



**REFERRING VET**

Dr. Glennon

Image shows a representative collection of reactive lymphoid cells from Shea. There are neutrophils present also.

**INVOICE NUMBER**

757



**DATE** 7/5/22 The information and recommendations provided are based on the images presented by the referring veterinarian. No evaluation can be communicated regarding pathology that was not visible in the image/video clips provided.

**INTERPRETED BY** L.D. McGill, DVM, Ph.D., DACVP Thank you for this referral. If the clinical or image interpretation does not parallel your findings or if I can be of any further assistance please contact me.

L.D. McGill, DVM,  
Ph.D., DACVP

**L.D. McGill, DVM, Ph.D., DACVP**  
8288 Top of the World Drive  
Cottonwood Heights, UT 84121  
ldmcgill.vetpath@gmail.com  
cell: 801-865-1220

**PATIENT**

Shea Roufanis

**SPECIES**

Canine

**BREED**

Labradoodle

**SEX**

Male Neutered

**AGE**

10y

**WEIGHT**

27 lbs

**HOSPITAL NAME**

New Bridge Veterinary  
Practice

**REFERRING VET**

Dr. Glennon

**INVOICE NUMBER**

757